



**PATIENT**

Griswold Aumann

**PRESENTING CLINICAL SIGNS**

Patient presented for possibly eating a shoelace 2 days ago. Has been eating and drinking normally up until this morning. Was not interested in food. Slightly tachy on mm, abdomen palpation normal

**SPECIES**

Canine

**RADIOGRAPHIC STUDY OF THE ABDOMEN**

Radiographs of the abdomen in three imaging planes are provided for review.

**BREED**

Goldendoodle

**RADIOGRAPHIC FINDINGS**

The surrounding bony structures are within normal limits, the growth plates are age related open.

No abnormalities of the extraabdominal soft tissues are noted. The abdominal wall is smooth and thin.

**SEX**

MA

The serosal detail is maintained throughout the peritoneal and retroperitoneal space.

The liver is appropriate in position, size and presents uniform opacity.

**AGE**

4 Months

The splenic head is in the anticipated position and within normal limits for size and opacity. The splenic body and tail are considered normal for position, size, shape and opacity.

Both kidneys are seen and present with normal size, shape, delineation and opacity. The urinary bladder is in its anticipated position. No radiopaque calculi are noted throughout the upper and lower urinary tract.

**INTERPRETED BY**

Sebastian Schaub, DVM  
Dr. med. vet. DipECVDI

The stomach is in its anticipated position and contains a mild to moderate amount of fluid. In the left lateral view of the abdomen, a rectangular, geometric mineral opaque body is seen in the region of the pyloric antrum.

**HOSPITAL NAME**

Boca Park Animal  
Hospital

The small intestinal loops are of even diameter and non-dilated, a small amount of gas is seen within the small intestinal loops and considered within normal limits.

The colon is seen in the expected position and contains a small amount of

**REFERRING VET**

Dr. Corinna Gorgon

**RADIOGRAPHIC DIAGNOSIS**

- Mild fluid filled adynamic appearing stomach
- Possible gastric foreign body
- Empty colon

**INVOICE**

51894

**INTERPRETATION OF THE FINDINGS & FURTHER RECOMMENDATIONS**

The mild fluid filled adynamic appearing stomach is most suggestive for gastritis with secondary functional gastric empty disorder. There is a small geometric object visible in the stomach – concerning for a small gastric foreign body; however, this might be an incidental finding. Recommend empirical management for possible gastritis/developing gastroenteritis. If clinical signs are refractory to therapy, recommend follow up radiographs after 12h of fasting or a complete abdominal ultrasound examination.

**DATE**

5-4-22



**PATIENT**

Griswold Aumann

**SPECIES**

Canine

**BREED**

Goldendoodle

**SEX**

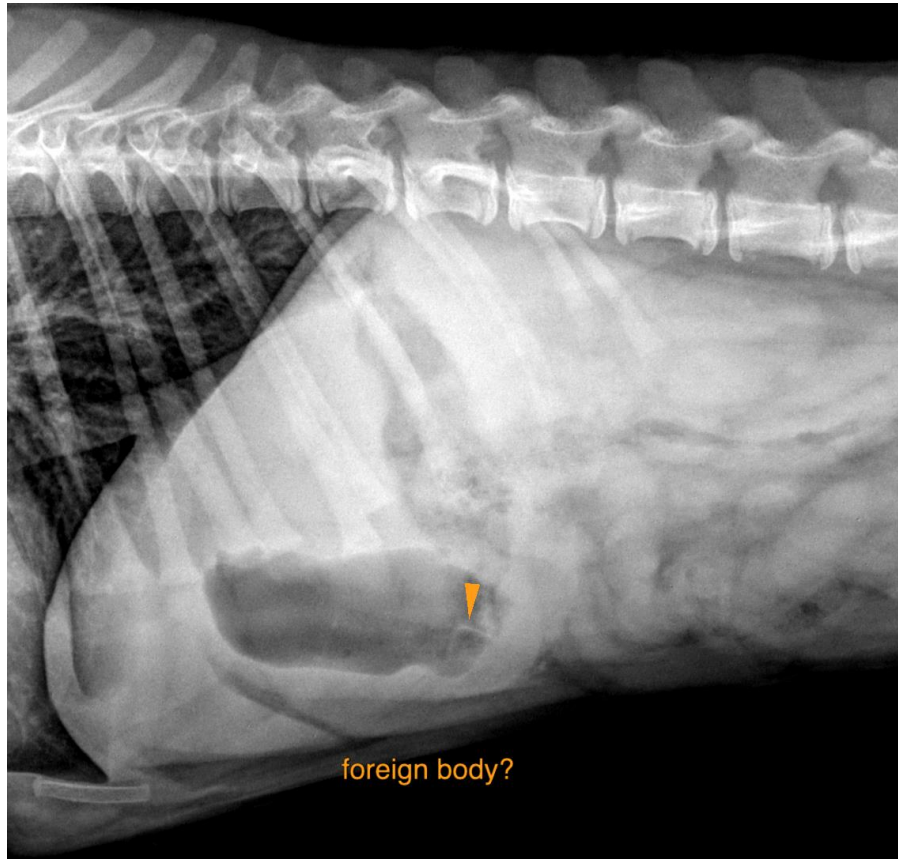
MA

**AGE**

4 Months

**INTERPRETED BY**

Sebastian Schaub, DVM  
Dr. med. vet. DipECVDI



**HOSPITAL NAME**

Boca Park Animal  
Hospital

**REFERRING VET**

Dr. Corinna Gorgon

**INVOICE**

51894

**DATE**

5-4-22

The information and recommendations provided are based on the images presented by the referring veterinarian/sonographer. No evaluation can be communicated regarding pathology that was not visible in the image/video clips provided.

Thank you for this referral. If the clinical or image interpretation does not parallel your findings or if I can be of any further assistance please contact me.

**Sebastian Schaub**, Sebastian Schaub, DVM, Dr. med. vet. DipECVDI  
sebast.schaub@gmail.com