



PATIENT

Bogie McDaniel

PRESENTING CLINICAL SIGNS

He will limp around and use his leg and then sometimes he won't put any weight on it. He usually will hold his leg up after he runs the property line. Shawna said that during the last big snow storm there was a lot of ice and Bogie was running around and he might have slipped.

SPECIES

Canine

Abnormal PE/Chem/CBC/UA Results: LIMPING LEFT HIND MEDIAL BUTTRESS LEFT HIND UNCOMFORTABLE TO EXTENSION OF STIFLE. HYPERPIGMENTATION AND ALOPECIA IN FLANKS (CHRONIC ALLERGIES)

BREED

Labrador Retriever
Mix

RADIOGRAPHIC STUDY OF THE PELVIS AND STIFLE JOINTS

Radiographs of the pelvis and stifle joints in two orthogonal imaging planes are provided for review.

SEX

MN

RADIOGRAPHIC FINDINGS

The osseous and surrounding soft tissue structures of the pelvis are within normal limits. Both coxofemoral joints present smooth osseous margins and congruent joint spaces.

The volume of the soft tissue shadow of the left thigh musculature is moderately decreased.

The periarticular bones of the left stifle joint present mild to moderate osteophyte new bone formation and a moderate intracapsular soft tissue swelling is appreciated.

AGE

3 Years, 5 Months

The osseous and soft tissue structures of the right stifle joint present no abnormalities.

INTERPRETED BY

Sebastian Schaub, DVM
Dr. med. vet. DipECVDI

RADIOGRAPHIC DIAGNOSIS

- Moderate degenerative osteoarthritis left stifle joint
- Moderate articular swelling left stifle joint
- Disuse atrophy musculature left hind limb
- Normal pelvis and coxofemoral joints
- Normal right stifle joint

HOSPITAL NAME

Elizabeth Animal
Hospital

INTERPRETATION OF THE FINDINGS & FURTHER RECOMMENDATIONS

The radiographic study is consistent with left sided chronic degenerative osteoarthritis with concomitant joint effusion. The most-likely underlying cause is (partial) rupture of the cranial cruciate ligament with or without meniscal disease.

REFERRING VET

Kim Allyn, DVM

A positive drawer sign or tibial compression test (under general anesthesia) can be used to confirm the diagnosis.

INVOICE

51906

DATE

5-4-22



PATIENT

Bogie McDaniel

SPECIES

Canine

BREED

Labrador Retriever
Mix

SEX

MN

AGE

3 Years, 5 Months

INTERPRETED BY

Sebastian Schaub, DVM
Dr. med. vet. DipECVDI

HOSPITAL NAME

Elizabeth Animal
Hospital

REFERRING VET

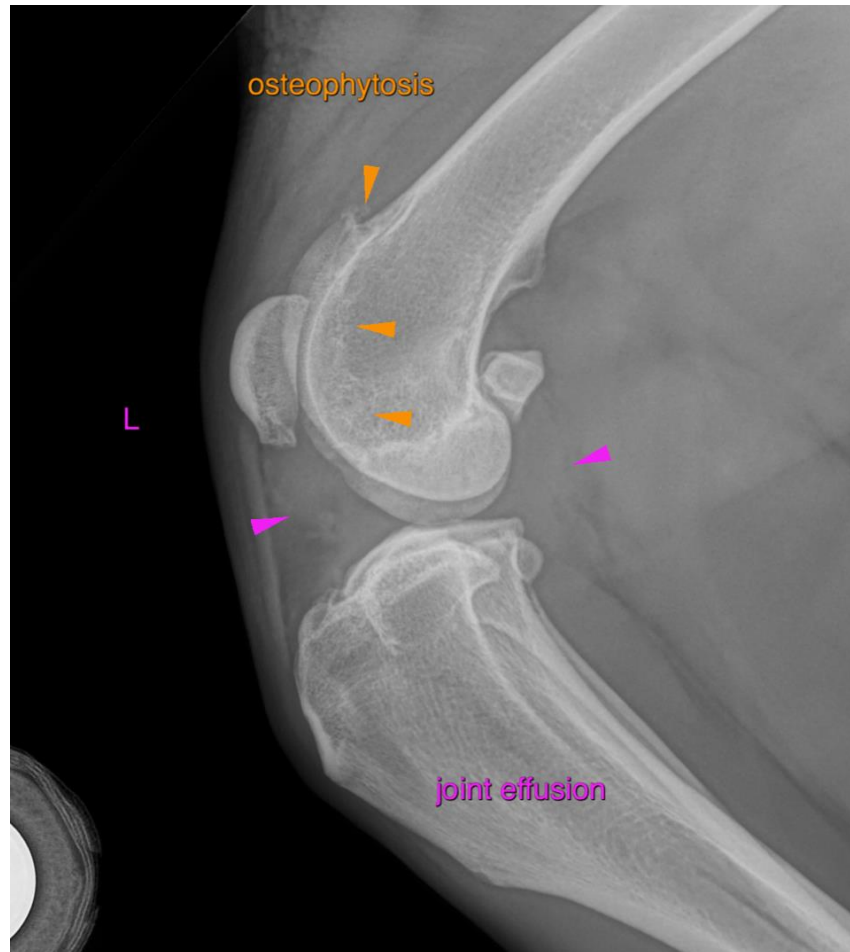
Kim Allyn, DVM

INVOICE

51906

DATE

5-4-22



The information and recommendations provided are based on the images presented by the referring veterinarian/sonographer. No evaluation can be communicated regarding pathology that was not visible in the image/video clips provided.

Thank you for this referral. If the clinical or image interpretation does not parallel your findings or if I can be of any further assistance please contact me.

Sebastian Schaub, Sebastian Schaub, DVM, Dr. med. vet. DipECVDI
sebast.schaub@gmail.com