

**PATIENT**

Sarah Haney

**PRESENTING CLINICAL SIGNS**

Pet presented for a dental cleaning

**COMPUTED TOMOGRAPHY OF THE SKULL****SPECIES**

Canine

A high resolution plain CT study of the skull is provided for review.

**BREED**

Chihuahua

**COMPUTED TOMOGRAPHIC FINDINGS**

The tooth elements 101-103, 105-107, 110, 202, 203, 206, 207, 210, 301-303, 305, 306, 311, 402-406 and 411 are absent. The palatine mesial root of triadan 108 presents a significant widening of the periodontal space. Triadan 204 presents a moderate widening of the periodontal space. The crown of triadan 201 is absent and the root is retained within the alveolar crest – the periodontal space is smooth and thin. A retained fragment of the tooth root of triadan 303 is noted, without signs of infection. The crown of triadan 401 is fractured and a moderate horizontal bone loss of the alveolar bone is appreciated.

**SEX**

FS

The nasal cavity presents the expected aerated spaces between thin & even conchae and turbinates with smooth mucosal lining.

**AGE**

15 Years

Both temporomandibular joints present congruent joint spaces with even subchondral bone surfaces and are considered within normal limits.

Both tympanic bullae are aerated, the mucosal lining is not seen, the bony wall is smooth and thin. The horizontal segment of the right external ear canal is segmentally moderately narrowed.

**INTERPRETED BY**

Sebastian Schaub, DVM  
Dr. med. vet. DipECVDI

**COMPUTED TOMOGRAPHIC DIAGNOSIS**

- Periodontal disease 108, 204 and 401
- Complicated dental fracture 401
- Retained fragments of the tooth roots of triadan 201 and 303 without signs of infection
- Multiple absent teeth, see above
- Suspect right sided otitis externa

**HOSPITAL NAME**

Cranberry Holistic  
Pet Care

**INTERPRETATION OF THE FINDINGS & FURTHER RECOMMENDATIONS**

Multiple of the retained dental elements present evidence of clinically relevant periodontal disease. A complete dental workup has already been performed.

**REFERRING VET**

Cynthia Maro

**INVOICE**

52191

**DATE**

5-31-22



**PATIENT**

Sarah Haney

**SPECIES**

Canine

**BREED**

Chihuahua

**SEX**

FS

**AGE**

15 Years

**INTERPRETED BY**

Sebastian Schaub, DVM  
Dr. med. vet. DipECVDI

**HOSPITAL NAME**

Cranberry Holistic  
Pet Care

**REFERRING VET**

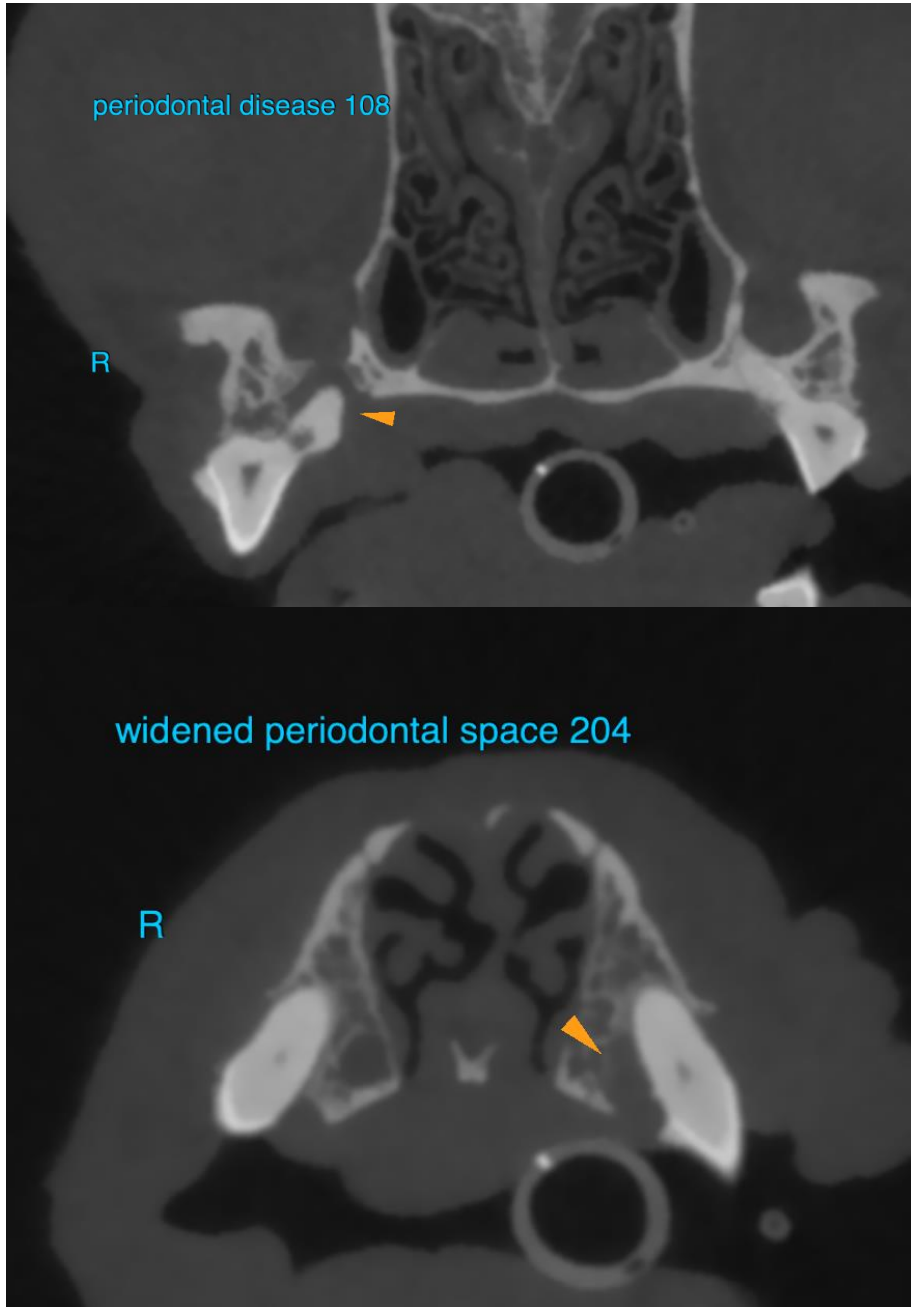
Cynthia Maro

**INVOICE**

52191

**DATE**

5-31-22





**PATIENT**

Sarah Haney

**SPECIES**

Canine

**BREED**

Chihuahua

**SEX**

FS

**AGE**

15 Years

**INTERPRETED BY**

Sebastian Schaub, DVM  
Dr. med. vet. DipECVDI

**HOSPITAL NAME**

Cranberry Holistic  
Pet Care

**REFERRING VET**

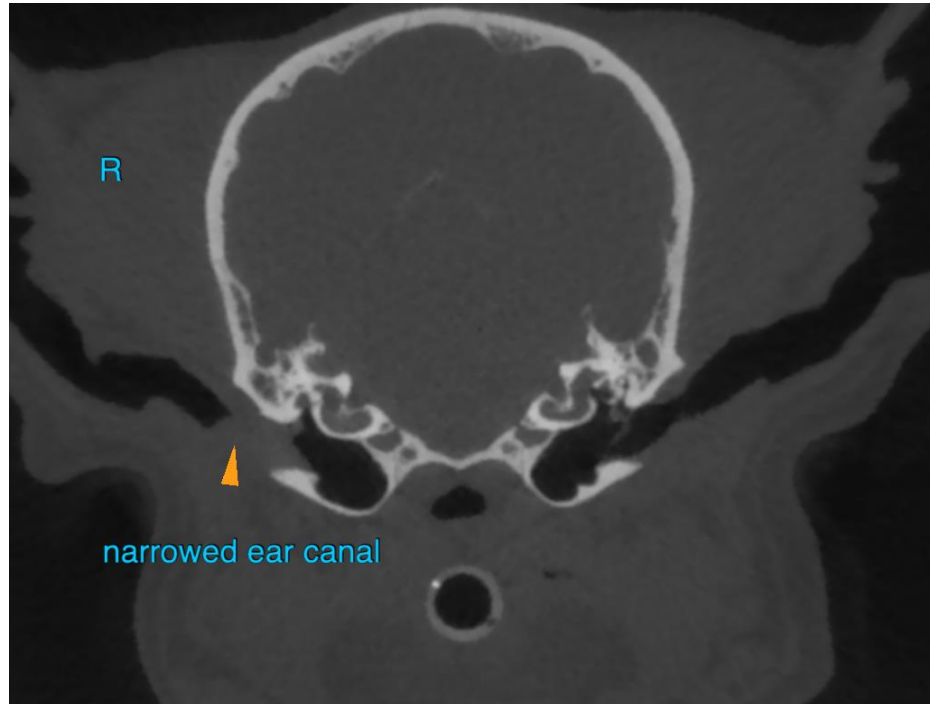
Cynthia Maro

**INVOICE**

52191

**DATE**

5-31-22



The information and recommendations provided are based on the images presented by the referring veterinarian/sonographer. No evaluation can be communicated regarding pathology that was not visible in the image/video clips provided.

Thank you for this referral. If the clinical or image interpretation does not parallel your findings or if I can be of any further assistance please contact me.

**Sebastian Schaub**, Sebastian Schaub, DVM, Dr. med. vet. DipECVDI  
sebast.schaub@gmail.com