



PATIENT

Phoebe Beach Garcia

PRESENTING CLINICAL SIGNS

wheezing at night, intermittent coughing.

SPECIES

Canine

RADIOGRAPHIC STUDY OF THE THORAX

Radiographs of the thorax in three imaging planes are provided for review.

BREED

Spaniel Mix

RADIOGRAPHIC FINDINGS

The surrounding bony structures are within normal limits.

The extrathoracic soft tissues present homogeneous without abnormalities.

The heart is of normal size and shape, there is no evidence of cardiac chamber or vascular enlargement. The pulmonary vasculature is within normal limits.

SEX

Female Spayed

The cranial mediastinum presents the expected soft tissue opacity. The mediastinal width is less than twice the width of the vertebral column at the same level.

The trachea is normal in diameter and presents the anticipated course. The luminal outline of the trachea is smooth.

AGE

6 years

Generalized mild to moderate peribronchial cuffing is appreciated.

The lung parenchyma presents the expected architecture and opacity; the intrapulmonary vascular branching is seen up to the third order lung vessels.

INTERPRETED BY

Sebastian Schaub, DVM
Dr. med. vet. DipECVDI

The diaphragm is well delineated with even surface and the expected mild cranial bulging of the diaphragmatic cupola.

RADIOGRAPHIC DIAGNOSIS

- Generalized mild to moderate bronchial lung pattern

HOSPITAL NAME

Northshore
Veterinary Hospital

INTERPRETATION OF THE FINDINGS & FURTHER RECOMMENDATIONS

The bronchial lung pattern is indicative for bronchitis and primary inflammatory non-infectious bronchitis – such as eosinophilic, lymphocytic plasmocytic, allergic – or infectious causes (e.g. viral, bacterial, parasitic, protozoal) are considerations. Bronchoscopy including BAL would be ideal for further workup. Complementing workup by a fecal exam can be used to rule out parasitic infection.

REFERRING VET

Kimberly Barron

INVOICE

52216

DATE

5-31-22



PATIENT

Phoebe Beach Garcia

SPECIES

Canine

BREED

Spaniel Mix

SEX

Female Spayed

AGE

6 years

INTERPRETED BY

Sebastian Schaub, DVM
Dr. med. vet. DipECVDI

HOSPITAL NAME

Northshore
Veterinary Hospital

REFERRING VET

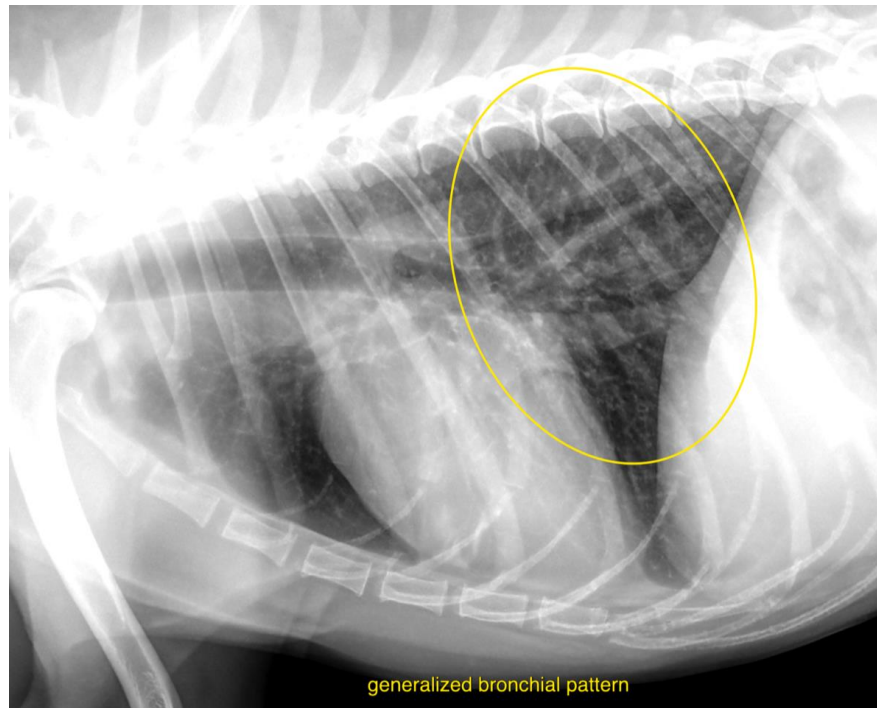
Kimberly Barron

INVOICE

52216

DATE

5-31-22



The information and recommendations provided are based on the images presented by the referring veterinarian/sonographer. No evaluation can be communicated regarding pathology that was not visible in the image/video clips provided.

Thank you for this referral. If the clinical or image interpretation does not parallel your findings or if I can be of any further assistance please contact me.

Sebastian Schaub, Sebastian Schaub, DVM, Dr. med. vet. DipECVDI
sebast.schaub@gmail.com