SonoPath Teleradiology

EDUCATIONAL TELECONSULTATION SERVICES™

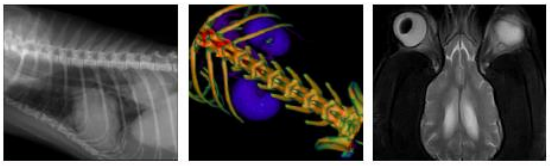

SonoPath.com
1-800-838-4268 info@sonopath.com

PATIENT

Otis Tisch

SPECIES

Canine

BREED

French Bulldog

SEX

Male Neutered

AGE

1 Year

INTERPRETED BY

Sebastian Schaub, DVM
Dr. med. vet. DipECVDI

HOSPITAL NAME

Green Dog Dental and Wellness

REFERRING VET

Ren Garcia, DVM

INVOICE

52200

DATE

5-31-22

PRESENTING CLINICAL SIGNS

RECENT DX SUSPECTED THORACOLUMBAR IVDD AT EMERGENCY FACILITY, OWNER REQUESTING FULL WORK UP. 5/23 - PRESENTED FOR TREMBLING X 2 DAYS WITH LIP LICKING AND HARD SWALLOWING. NO DX

COMPUTED TOMOGRAPHY OF THE CERVICAL, THORACIC AND LUMBAR SPINE

A pre- and post-contrast CT study of the entire spine is provided for review.

COMPUTED TOMOGRAPHIC FINDINGS

The left tympanic bulla is filled with soft tissue attenuating material. The osseous lining of the left tympanic bulla is mildly thickened and smooth.

The osseous and soft tissue structures of the cervical spine are within normal limits.

T3, T6 and T9 present as hemivertebra with secondary kyphosis of the thoracic spine level with T6.

Level with the intervertebral disc space L3/L4, mild hyperattenuating material is seen in the right ventral aspect of the vertebral canal, occupying approximately 10% of the cross-sectional area of the vertebral canal at the same level. The mild hypoattenuating material is extending cranially up to the level of the cranial third of the vertebral body of L3 and caudally up to the cranial vertebral endplate of L4.

The caudal vertebral endplate of L7 is misshapen, presenting a mild irregular marginated defect of the subchondral bone in the right aspect.

COMPUTED TOMOGRAPHIC DIAGNOSIS

- Intervertebral disc extrusion L3/L4 with potential dynamic spinal cord compression
- Hemivertebra T3, T6 and T9 with segmental kyphosis of the thoracic spine
- Suspect disturbed ossification caudal vertebral endplate L7 – incidental but might predispose for discopathy
- Left sided chronic otitis media
- Normal cervical spine

INTERPRETATION OF THE FINDINGS & FURTHER RECOMMENDATIONS

The intervertebral disc extrusion L3/L4 is a plausible explanation for pain. As the amount of material in the vertebral canal is only mild, conservative management appears promising. If clinical signs are refractory to empirical management by the means of rest and pain management or neurological deficits develop, surgical decompression appears beneficial – repeating the CT study prior to surgical intervention is beneficial to rule out discopathy in a different location.

SonoPath Teleradiology

EDUCATIONAL TELECONSULTATION SERVICES™

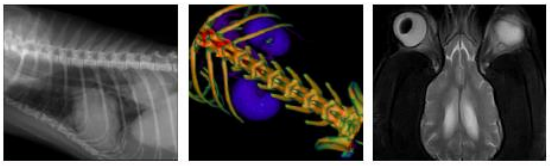

SonoPath.com
1-800-838-4268 info@sonopath.com

PATIENT

Otis Tisch

SPECIES

Canine

BREED

French Bulldog

SEX

Male Neutered

AGE

1 Year

INTERPRETED BY

Sebastian Schaub, DVM
Dr. med. vet. DipECVDI

HOSPITAL NAME

Green Dog Dental and Wellness

REFERRING VET

Ren Garcia, DVM

INVOICE

52200

DATE

5-31-22

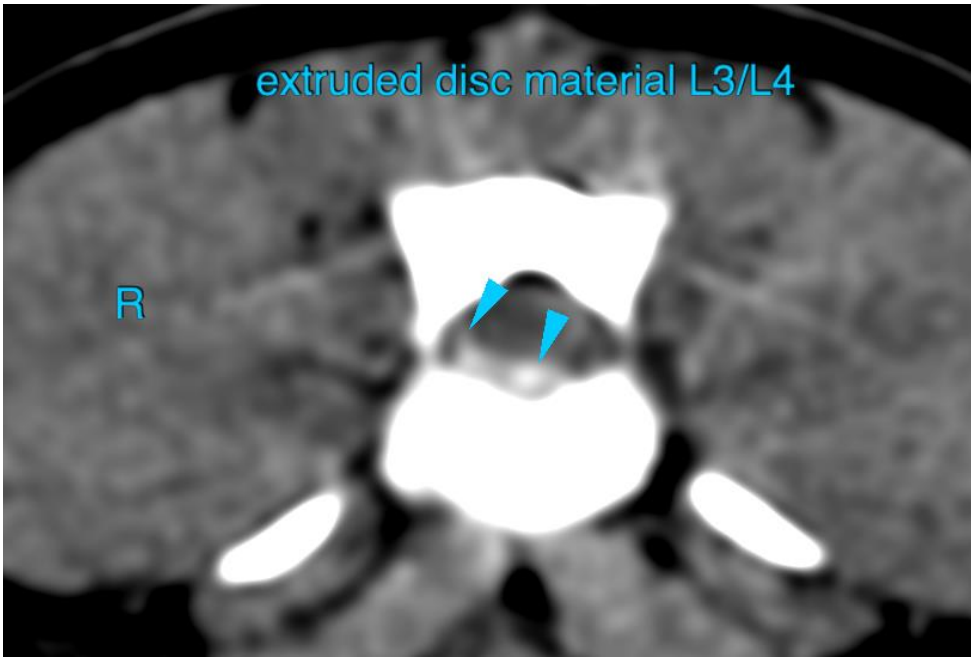

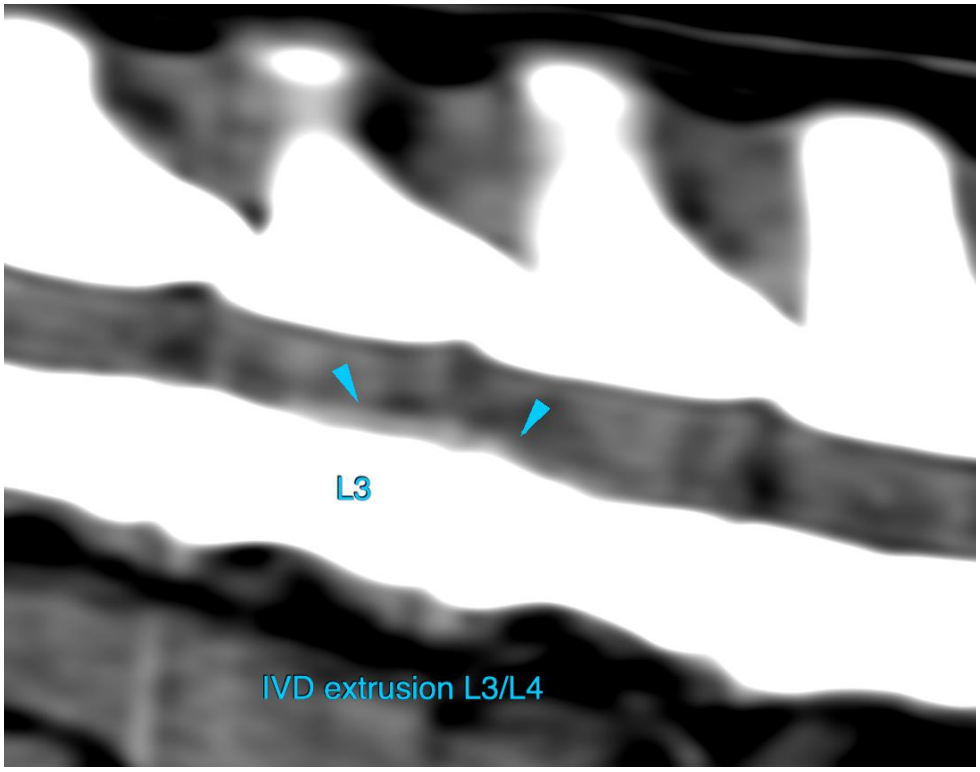

SonoPath Teleradiology

EDUCATIONAL TELECONSULTATION SERVICES™

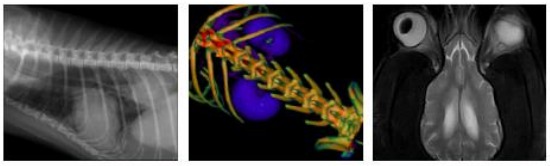

SonoPath.com
1-800-838-4268 info@sonopath.com

PATIENT

Otis Tisch

SPECIES

Canine

BREED

French Bulldog

SEX

Male Neutered

AGE

1 Year

INTERPRETED BY

Sebastian Schaub, DVM
Dr. med. vet. DipECVDI

HOSPITAL NAME

Green Dog Dental and Wellness

REFERRING VET

Ren Garcia, DVM

INVOICE

52200

DATE

5-31-22

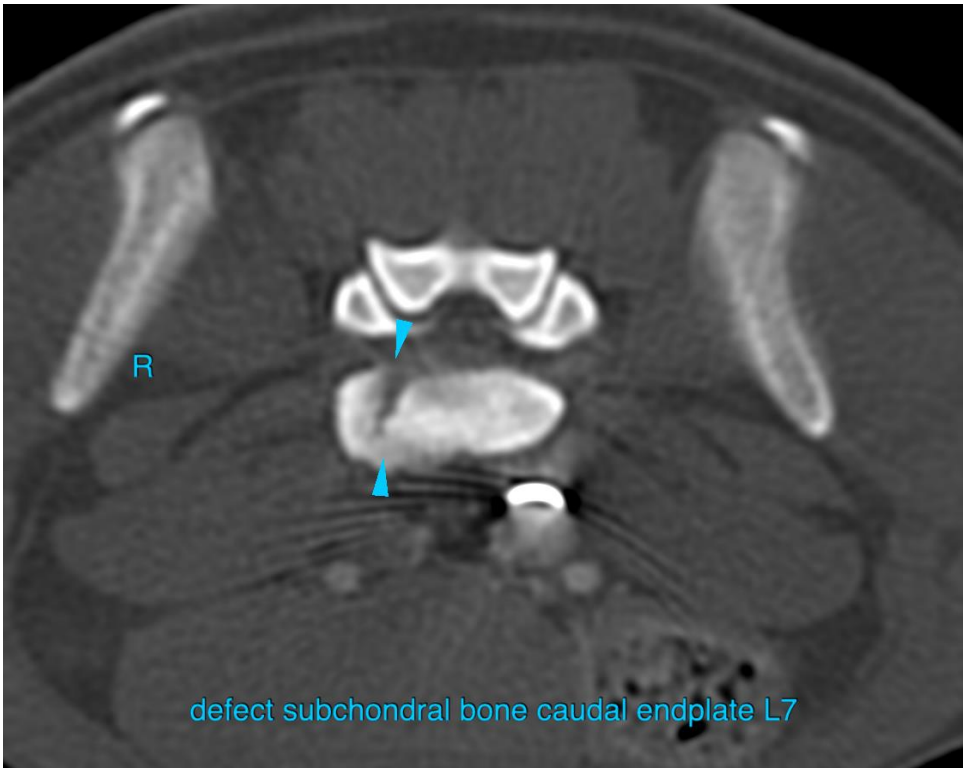

The information and recommendations provided are based on the images presented by the referring veterinarian/sonographer. No evaluation can be communicated regarding pathology that was not visible in the image/video clips provided.

Thank you for this referral. If the clinical or image interpretation does not parallel your findings or if I can be of any further assistance please contact me.

Sebastian Schaub, Sebastian Schaub, DVM, Dr. med. vet. DipECVDI
sebast.schaub@gmail.com