



PATIENT

Miles McDowell

PRESENTING CLINICAL SIGNS

bloody mucous coming from anus , vomiting bile noticed once a day since May 24 lost 4 pounds since September

Abnormal PE/Chem/CBC/UA Results: QAR temp 39.3 C , straining .. inflamed penis , pancreatitis fpli 35.5 (0-35) normal CBC ,kidney values, T4 ,glucose pending UA results

SPECIES

Feline

RADIOGRAPHIC STUDY OF THE ABDOMEN

Radiographs of the abdomen in three imaging planes are provided for review.

BREED

Domestic Shorthair

RADIOGRAPHIC FINDINGS

The surrounding bony structures are within normal limits.

No abnormalities of the extraabdominal soft tissues are noted. The abdominal wall is smooth and thin.

SEX

Male Neuter

The serosal detail is maintained throughout the peritoneal and retroperitoneal space.

The liver is appropriate in position, size and presents uniform opacity.

AGE

11 Years

The splenic head is in the anticipated position and within normal limits for size and opacity.

Both kidneys are seen and present with normal size, shape, delineation and opacity. The urinary bladder is in its anticipated position. No radiopaque calculi are noted throughout the upper and lower urinary tract.

INTERPRETED BY

Sebastian Schaub, DVM
Dr. med. vet. DipECVDI

The stomach is in its anticipated position and presents normal content.

The small intestinal loops are of even diameter and non-dilated, a small amount of gas is seen within the small intestinal loops and considered within normal limits.

HOSPITAL NAME

St. Catherine's Animal
Hospital

The colon is seen in the expected position and contains a moderate amount of fecal material with an increased radiopacity.

RADIOGRAPHIC DIAGNOSIS

- Possible constipation

REFERRING VET

Dr. Mena

INTERPRETATION OF THE FINDINGS & FURTHER RECOMMENDATIONS

Check for normal defecation of the patient, as the amount and density of the fecal material in the colon is concerning for constipation. Digital rectal examination can be used to rule out stricture or mural lesions level with the rectum.

INVOICE

52196

DATE

5-31-22



PATIENT

Miles McDowell

SPECIES

Feline

BREED

Domestic Shorthair

SEX

Male Neuter

AGE

11 Years

INTERPRETED BY

Sebastian Schaub, DVM
Dr. med. vet. DipECVDI

HOSPITAL NAME

St. Catherine's Animal
Hospital

REFERRING VET

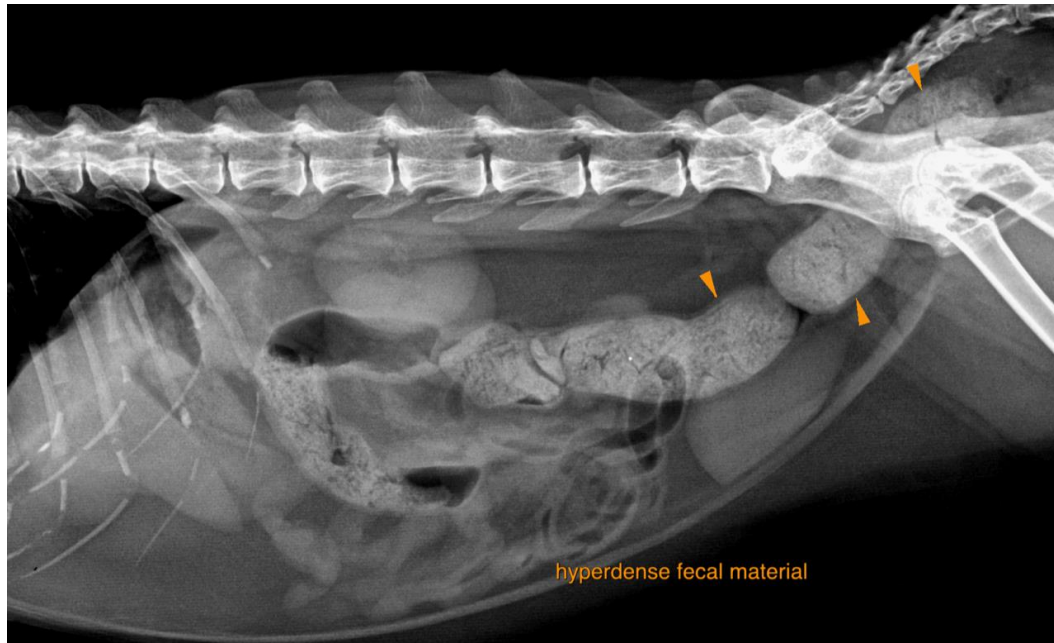
Dr. Mena

INVOICE

52196

DATE

5-31-22



The information and recommendations provided are based on the images presented by the referring veterinarian/sonographer. No evaluation can be communicated regarding pathology that was not visible in the image/video clips provided.

Thank you for this referral. If the clinical or image interpretation does not parallel your findings or if I can be of any further assistance please contact me.

Sebastian Schaub, Sebastian Schaub, DVM, Dr. med. vet. DipECVDI
sebast.schaub@gmail.com