



**PATIENT**

Totis Guler

**PRESENTING CLINICAL SIGNS**

presented for COHAT and extraction of 204 CCF. Also extracted 203, 208 and 209.

**SPECIES**

Feline

**COMPUTED TOMOGRAPHY OF THE SKULL**

A high resolution plain CT study of the skull is provided for review.

**BREED**

DSH

**COMPUTED TOMOGRAPHIC FINDINGS**

The tip of the crown of triadan 204 is absent, exposing the pulp cavity to the dental surface. Major parts of the crown of triadan 203 are absent. Triadan 208 presents with an irregular resorptive lesion in the distal aspect and a horizontal fracture line is separating the distal root of triadan 208 from the crown. A small isolated mineralized body is seen in the soft tissues at the buccal aspect of triadan 208.

**SEX**

MN

The nasal cavity presents the expected aerated spaces between thin & even conchae and turbinates with smooth mucosal lining.

**AGE**

4 Years

Both temporomandibular joints present congruent joint spaces with even subchondral bone surfaces and are considered within normal limits.

Both tympanic bullae are aerated, the mucosal lining is not seen, the bony wall is smooth and thin. The external ear canals are within normal limits.

The submandibular and medial retropharyngeal lymph nodes are small and elongated with a normal short-to-long-axis-ratio is < 0.5, the attenuation pattern is uniform.

**INTERPRETED BY**

Sebastian Schaub, DVM  
Dr. med. vet. DipECVDI

**COMPUTED TOMOGRAPHIC DIAGNOSIS**

- Complicated dental fracture 203, 204
- Resorptive lesion 208 with dental fracture

**HOSPITAL NAME**

South Bay Animal  
Hospital & Pet Resort

**INTERPRETATION OF THE FINDINGS & FURTHER RECOMMENDATIONS**

Triadan 203 and 204 present with complicated dental fracture, without abscess formation. A complete dental workup has already been performed.

**REFERRING VET**

Dr. Ravinder Atwal

**INVOICE**

52164

**DATE**

5-30-22



**PATIENT**

Totis Guler

**SPECIES**

Feline

**BREED**

DSH

**SEX**

MN

**AGE**

4 Years

**INTERPRETED BY**

Sebastian Schaub, DVM  
Dr. med. vet. DipECVDI

**HOSPITAL NAME**

South Bay Animal  
Hospital & Pet Resort

**REFERRING VET**

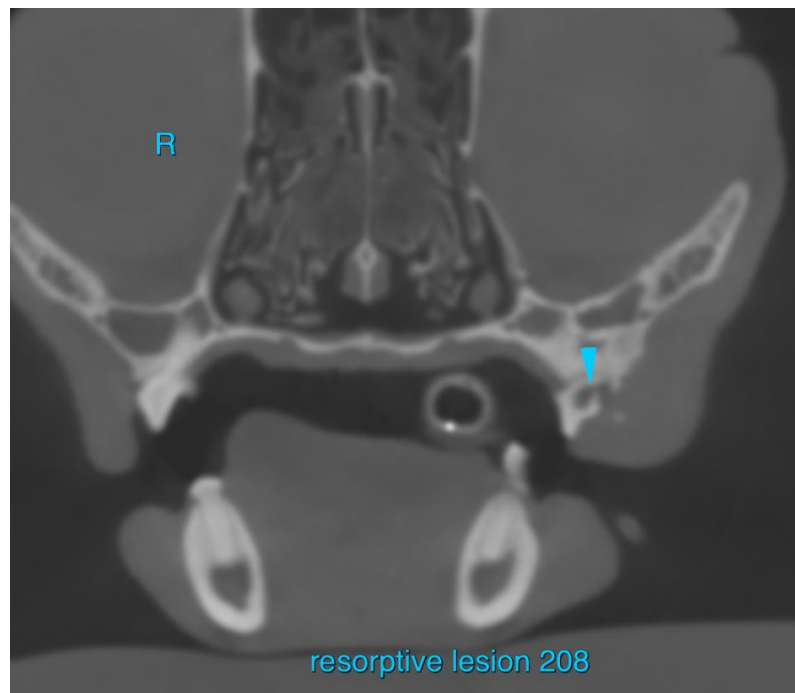
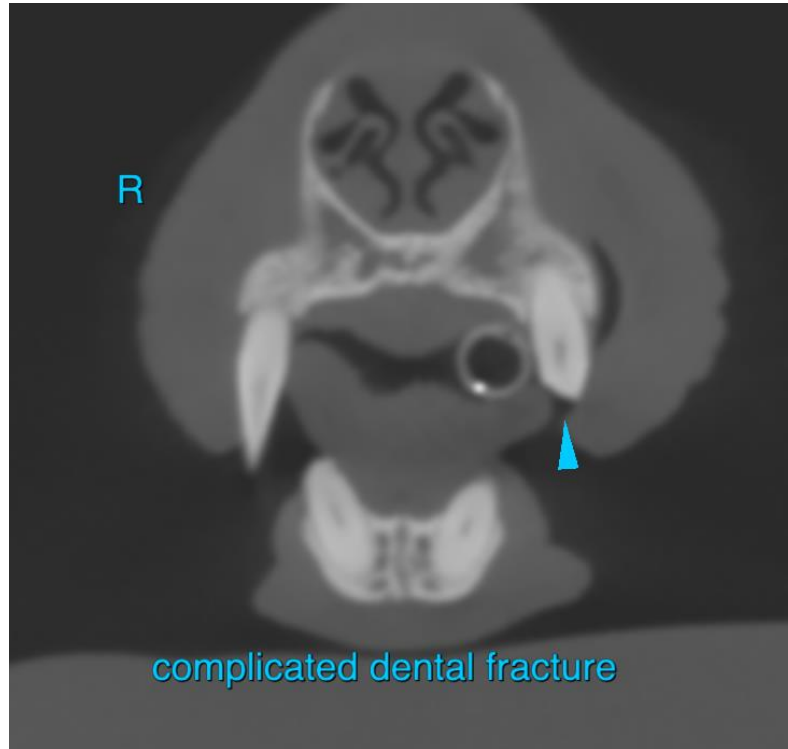
Dr. Ravinder Atwal

**INVOICE**

52164

**DATE**

5-30-22





**PATIENT**

Totis Guler

**SPECIES**

Feline

The information and recommendations provided are based on the images presented by the referring veterinarian/sonographer. No evaluation can be communicated regarding pathology that was not visible in the image/video clips provided.

**BREED**

DSH

Thank you for this referral. If the clinical or image interpretation does not parallel your findings or if I can be of any further assistance please contact me.

**Sebastian Schaub**, Sebastian Schaub, DVM, Dr. med. vet. DipECVDI  
sebast.schaub@gmail.com

**SEX**

MN

**AGE**

4 Years

**INTERPRETED BY**

Sebastian Schaub, DVM  
Dr. med. vet. DipECVDI

**HOSPITAL NAME**

South Bay Animal  
Hospital & Pet Resort

**REFERRING VET**

Dr. Ravinder Atwal

**INVOICE**

52164

**DATE**

5-30-22