

**PATIENT**

Gus Dalzell

PRESENTING CLINICAL SIGNS

Chronic unilater nasal discharge, left side

SPECIES

Canine

COMPUTED TOMOGRAPHY OF THE SKULL

A high resolution pre- and post-contrast CT study of the skull is provided for review.

BREED

Golden Mix

COMPUTED TOMOGRAPHIC FINDINGS

Triadan 107 and 207 are absent.

In both nasal cavities, a mild to moderate amount of fluid attenuating material is present – most pronounced in the ventral nasal meatus bilaterally. Moderate destruction of the nasal conchal & turbinate structures is appreciated.

SEX

MN

Both temporomandibular joints present congruent joint spaces with even subchondral bone surfaces and are considered within normal limits.

Both tympanic bullae are aerated, the mucosal lining is not seen, the bony wall is smooth and thin. The external ear canals are within normal limits.

AGE

1 Year, 6 Months

The brain presents no deviation from normal anatomy and symmetry. The brain parenchyma is homogeneous and within normal limits for attenuation and distribution of contrast enhancement. The ventricular system is non-dilated and symmetric.

The submandibular and medial retropharyngeal lymph nodes are small and elongated with a normal short-to-long-axis-ratio is < 0.5, the attenuation and contrast enhancement pattern is uniform.

INTERPRETED BYSebastian Schaub, DVM
Dr. med. vet. DipECVDI**COMPUTED TOMOGRAPHIC DIAGNOSIS**

- Destructive rhinitis
- Absent triadan 107&207

HOSPITAL NAMEAloha Pet & Bird
Hospital**INTERPRETATION OF THE FINDINGS & FURTHER RECOMMENDATIONS**

The destructive rhinitis is suggestive for non-specific rhinitis (e.g. lymphocytic plasmocytic, eosinophilic) ± bacterial or less likely mycotic superinfection (no signs for hyperostosis). The chronicity of clinical signs and bilateral distribution of nasal changes is rendering the odds for nasal foreign material low. Recommend rhinoscopy including sampling for microbial culture and histopathology to confirm the diagnosis and rule out fungal infection.

REFERRING VET

Dr. Manuel Pepen

INVOICE

52166

DATE

5-30-22



PATIENT

Gus Dalzell

SPECIES

Canine

BREED

Golden Mix

SEX

MN

AGE

1 Year, 6 Months

INTERPRETED BY

Sebastian Schaub, DVM
Dr. med. vet. DipECVDI

HOSPITAL NAME

Aloha Pet & Bird
Hospital

REFERRING VET

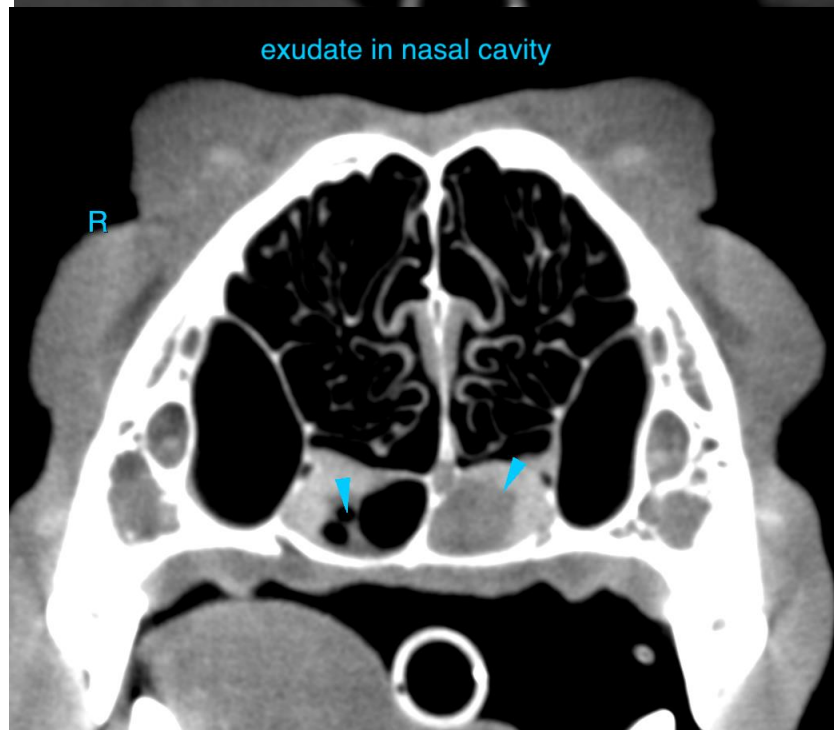
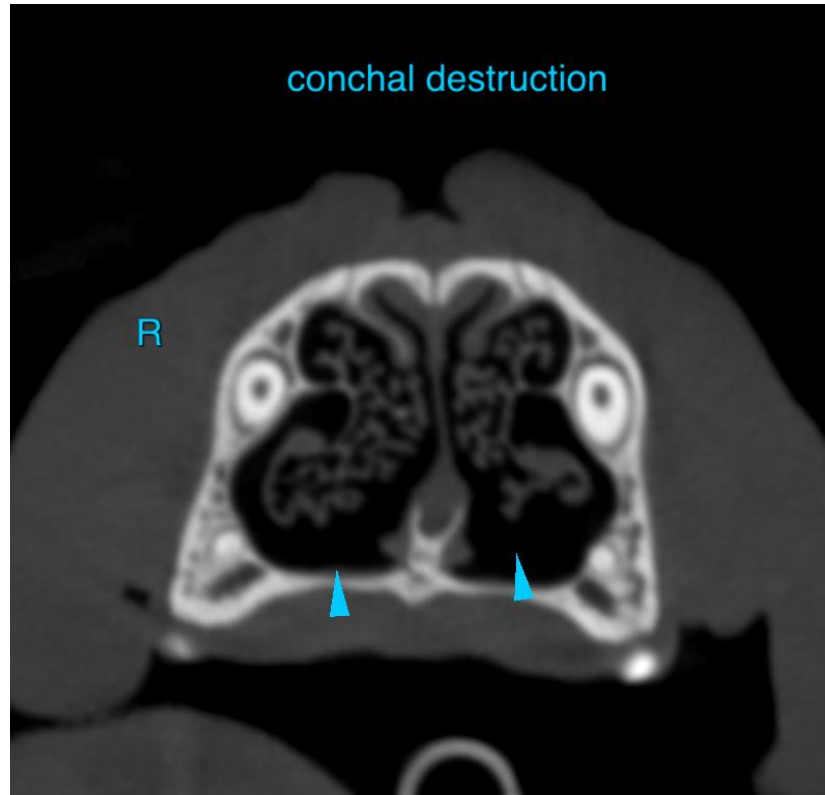
Dr. Manuel Pepen

INVOICE

52166

DATE

5-30-22





PATIENT

Gus Dalzell

SPECIES

Canine

The information and recommendations provided are based on the images presented by the referring veterinarian/sonographer. No evaluation can be communicated regarding pathology that was not visible in the image/video clips provided.

BREED

Golden Mix

Thank you for this referral. If the clinical or image interpretation does not parallel your findings or if I can be of any further assistance please contact me.

Sebastian Schaub, Sebastian Schaub, DVM, Dr. med. vet. DipECVDI
sebast.schaub@gmail.com

SEX

MN

AGE

1 Year, 6 Months

INTERPRETED BY

Sebastian Schaub, DVM
Dr. med. vet. DipECVDI

HOSPITAL NAME

Aloha Pet & Bird
Hospital

REFERRING VET

Dr. Manuel Pepen

INVOICE

52166

DATE

5-30-22