



PATIENT

Charlie Negoy

PRESENTING CLINICAL SIGNS

bloody Vomiting and very liquid bloody diarrhea since 2 days , lethargic , not eating , owner was suspecting that he might ate a pen
Abnormal PE/Chem/CBC/UA Results: Bloodwork unremarkable, fecal test pending.

SPECIES

K9

RADIOGRAPHIC STUDY OF THE ABDOMEN

Radiographs of the abdomen in two imaging planes are provided for review.

BREED

Old English Sheepdog

RADIOGRAPHIC FINDINGS

The surrounding bony structures are within normal limits.

No abnormalities of the extraabdominal soft tissues are noted. The abdominal wall is smooth and thin.

SEX

Male

The serosal detail is maintained throughout the peritoneal and retroperitoneal space.

The liver is appropriate in position, size and presents uniform opacity.

The splenic head is in the anticipated position and within normal limits for size and opacity. The splenic body and tail are considered normal for position, size, shape and opacity.

AGE

11 Months

Both kidneys are seen and present with normal size, shape, delineation and opacity. The urinary bladder is in its anticipated position. No radiopaque calculi are noted throughout the upper and lower urinary tract.

INTERPRETED BY

Sebastian Schaub, DVM
Dr. med. vet. DipECVDI

The stomach is in its anticipated position and empty, but a mild amount of fluid.

The small intestinal loops are of even diameter and non-dilated, a small amount of gas is seen within the small intestinal loops and considered within normal limits.

HOSPITAL NAME

Lakeshore Woods
Animal Hospital

The colon is empty.

RADIOGRAPHIC DIAGNOSIS

- Empty gastrointestinal tract

REFERRING VET

Dr. Masoud

INTERPRETATION OF THE FINDINGS & FURTHER RECOMMENDATIONS

The empty gastrointestinal tract in combination with the presenting clinical signs is suggestive for gastroenteritis. There is no evidence of radiopaque foreign material or signs for gastrointestinal mechanical obstruction. If clinical signs are refractory to empirical therapy, recommend follow up radiographs or a complete abdominal ultrasound examination; in some cases, a high ileus may lack classical radiographic signs of mechanical obstruction.

INVOICE

52163

DATE

5-30-22



PATIENT

Charlie Negoy

SPECIES

K9

BREED

Old English Sheepdog

SEX

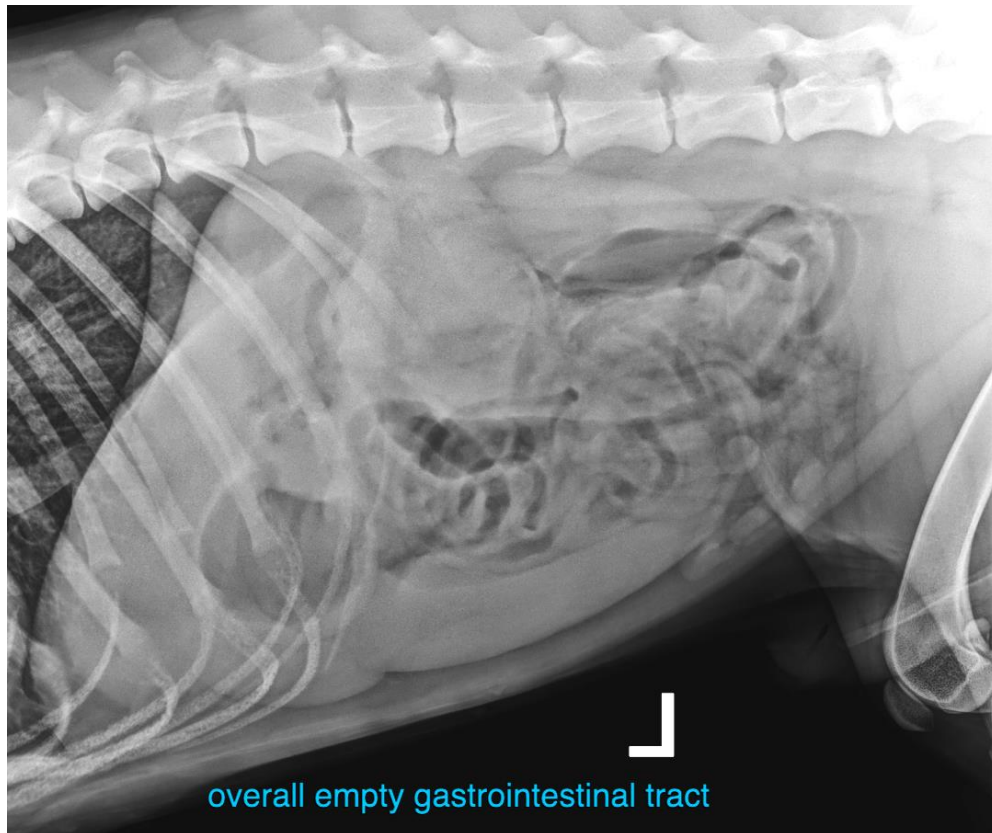
Male

AGE

11 Months

INTERPRETED BY

Sebastian Schaub, DVM
Dr. med. vet. DipECVDI



HOSPITAL NAME

Lakeshore Woods
Animal Hospital

REFERRING VET

Dr. Masoud

INVOICE

52163

DATE

5-30-22

The information and recommendations provided are based on the images presented by the referring veterinarian/sonographer. No evaluation can be communicated regarding pathology that was not visible in the image/video clips provided.

Thank you for this referral. If the clinical or image interpretation does not parallel your findings or if I can be of any further assistance please contact me.

Sebastian Schaub, Sebastian Schaub, DVM, Dr. med. vet. DipECVDI
sebast.schaub@gmail.com