



PATIENT PRESENTING CLINICAL SIGNS

Larry Larkin Repeat Chest rads for dog with a chronic cough for past 8 months. Chest rads done and read by you all on 12/22/22. Cough seemed to get a bit better and then has flared more in last month or so. Hx of mass in liver.

SPECIES Abnormal PE/Chem/CBC/UA Results: ALKP 2285 ALT 574 AST 178

Canine **RADIOGRAPHIC STUDY OF THE THORAX**

Radiographs of the thorax in two imaging planes are provided for review.

BREED RADIOGRAPHIC FINDINGS

Labrador Retriever The surrounding bony structures are within normal limits.

The extrathoracic soft tissues present homogeneous without abnormalities.

SEX The heart is of normal size and shape, there is no evidence of cardiac chamber or vascular enlargement. The pulmonary vasculature is within normal limits.

MN The cranial mediastinum presents the expected soft tissue opacity. The mediastinal width is less than twice the width of the vertebral column at the same level.

AGE The trachea is normal in diameter and presents the anticipated course. The luminal outline of the trachea is smooth.

12 A mild increased visibility of the bronchial wall is appreciated.

INTERPRETED BY The lung parenchyma presents the expected architecture and opacity; the intrapulmonary vascular branching is seen up to the third order lung vessels.

Sebastian Schaub, DVM
Dr. med. vet. DipECVDI

The diaphragm is well delineated with even surface and the expected mild cranial bulging of the diaphragmatic cupola.

HOSPITAL NAME RADIOGRAPHIC DIAGNOSIS

Healing Paws • Mild bronchial pattern

REFERRING VET INTERPRETATION OF THE FINDINGS & FURTHER RECOMMENDATIONS

Jennifer Levitsky The bronchial walls present with a mild increased visibility, in comparison to the preceding radiographic study – potentially supporting the diagnosis of inflammatory non-infectious bronchitis (e.g. eosinophilic, lymphocytic plasmocytic, neutrophilic, mixed).

INVOICE There are no signs for pulmonary metastatic disease.

51874

DATE

5-3-22



PATIENT

Larry Larkin

SPECIES

Canine

BREED

Labrador Retriever

SEX

MN

AGE

12

INTERPRETED BY

Sebastian Schaub, DVM
Dr. med. vet. DipECVDI

HOSPITAL NAME

Healing Paws

REFERRING VET

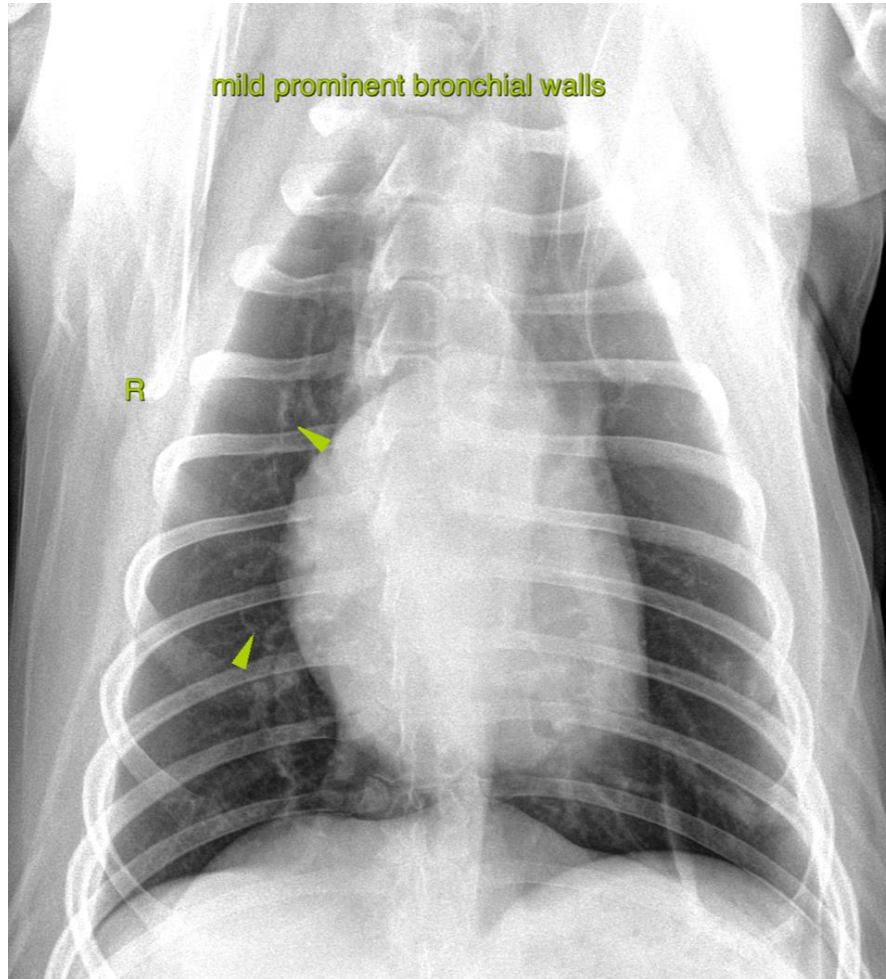
Jennifer Levitsky

INVOICE

51874

DATE

5-3-22



The information and recommendations provided are based on the images presented by the referring veterinarian/sonographer. No evaluation can be communicated regarding pathology that was not visible in the image/video clips provided.

Thank you for this referral. If the clinical or image interpretation does not parallel your findings or if I can be of any further assistance please contact me.

Sebastian Schaub, Sebastian Schaub, DVM, Dr. med. vet. DipECVDI
sebast.schaub@gmail.com