

**PATIENT**

Gracee Perkins

**PRESENTING CLINICAL SIGNS**

Unable to walk/ urinate. Px was WNL at 4pm May 2, was walking down stairs, sudden knuckling (no fall noted). Owner noted px limping on front limb a few weeks ago - resolved on own.

**SPECIES**

Canine

**COMPUTED TOMOGRAPHY OF THE SPINE**

A high resolution pre- and post-contrast CT study of the cervical, thoracic and lumbar spine is provided for review.

**BREED**

Dachshund

THE LAST RIB BEARING VERTEBRA IS COUNTED AS T13.

The osseous and surrounding soft tissue structures of the cervical spine present without abnormalities, but the mild mineralization of the intervertebral discs.

**SEX**

FS

Level with the intervertebral disc space T12/T13, heterogeneous hyperattenuating material is seen in the left lateroventral aspect of the vertebral canal, occupying approximately up to 70% of the cross-sectional area of the vertebral canal at the same level. The hyperattenuating material is extending cranially up to the mid third of the vertebral body of T12 and caudally up to the cranial vertebral endplate of T13; the dural tube at the same level is displaced to the right and dorsally and compressed.

**AGE**

6 Years

Eight lumbar vertebra are present. L7 presents asymmetrically shaped transverse processes, articulating with the sacroiliac joints.

**INTERPRETED BY**

Sebastian Schaub, DVM  
Dr. med. vet. DipECVDI

Multifocal punctuate mineralization of the intervertebral discs is appreciated.

**COMPUTED TOMOGRAPHIC DIAGNOSIS**

- Intervertebral disc extrusion T12/T13 with compressive myelopathy, from the left lateroventral aspect
- Multifocal chondroid disc degeneration
- Asymmetric lumbosacral transitional vertebra (Type III)

**HOSPITAL NAME**

Bridgwater  
Veterinary Hospital  
and Wellness Centre

**INTERPRETATION OF THE FINDINGS & FURTHER RECOMMENDATIONS**

The intervertebral disc extrusion T12/T13 from the left, is a plausible explanation for paraparesis. Surgical decompression is considered as the therapy of choice.

**REFERRING VET**

Dr. Watts

**INVOICE**

51868

**DATE**

5-3-22



**PATIENT**

Gracee Perkins

**SPECIES**

Canine

**BREED**

Dachshund

**SEX**

FS

**AGE**

6 Years

**INTERPRETED BY**

Sebastian Schaub, DVM  
Dr. med. vet. DipECVDI

**HOSPITAL NAME**

Bridgwater  
Veterinary Hospital  
and Wellness Centre

**REFERRING VET**

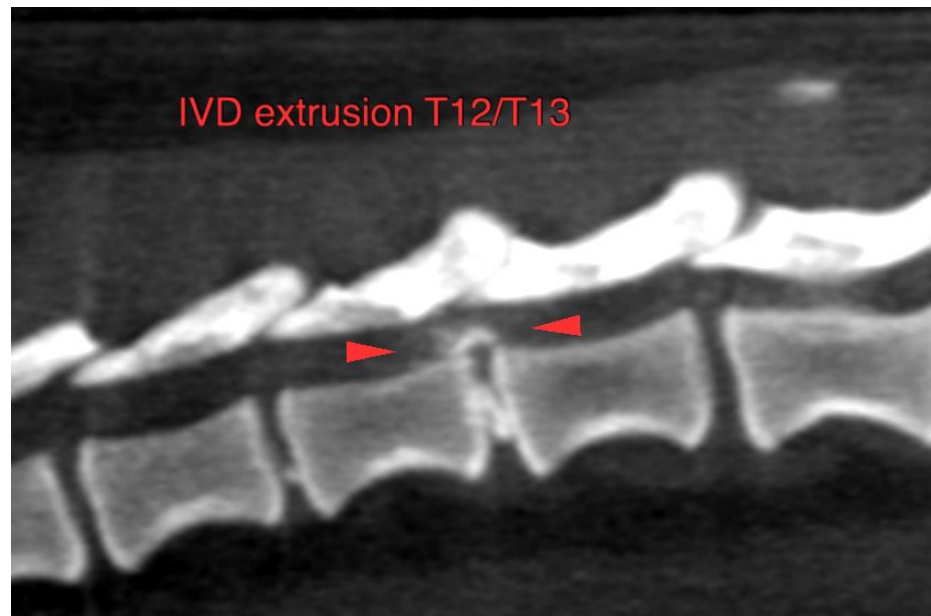
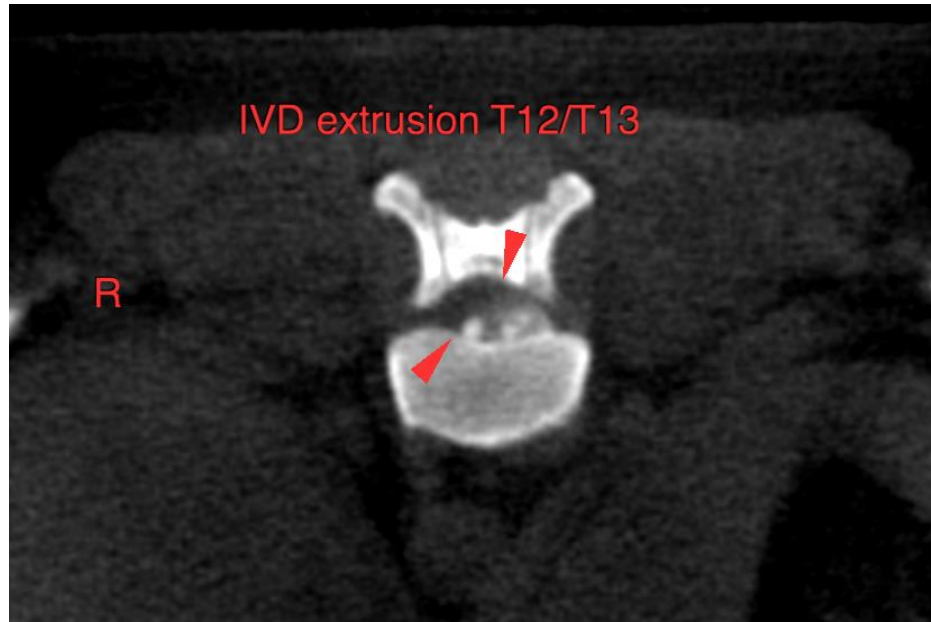
Dr. Watts

**INVOICE**

51868

**DATE**

5-3-22





**PATIENT**

Gracee Perkins

The information and recommendations provided are based on the images presented by the referring veterinarian/sonographer. No evaluation can be communicated regarding pathology that was not visible in the image/video clips provided.

**SPECIES**

Canine

Thank you for this referral. If the clinical or image interpretation does not parallel your findings or if I can be of any further assistance please contact me.

**Sebastian Schaub**, Sebastian Schaub, DVM, Dr. med. vet. DipECVDI  
sebast.schaub@gmail.com

**BREED**

Dachshund

**SEX**

FS

**AGE**

6 Years

**INTERPRETED BY**

Sebastian Schaub, DVM  
Dr. med. vet. DipECVDI

**HOSPITAL NAME**

Bridgwater  
Veterinary Hospital  
and Wellness Centre

**REFERRING VET**

Dr. Watts

**INVOICE**

51868

**DATE**

5-3-22