

PATIENT

Biblia Montenegro

SPECIES

Canine

BREED

French Bulldog

SEX

Female

AGE

2 Years

WEIGHT

33 Pounds

INTERPRETED BY

Sebastian Schaub, DVM
Dr. med. vet. DipECVDI

IMAGING PERFORMED BY

Amarilys Cala

HOSPITAL NAME

Miami Springs AH

REFERRING VET

Dr. Andres Perez

INVOICE

37242

DATE

5/29/26

PRESENTING CLINICAL SIGNS

History: Chronic pain and limping of the right front paw for 2 weeks. Pain elicited on palpation between C2 and C6.

COMPUTED TOMOGRAPHIC STUDY OF THE CERVICAL, THORACIC AND LUMBAR SPINE

A high resolution pre- and post-contrast CT study of the entire spine is provided for review.

COMPUTED TOMOGRAPHIC FINDINGS

Level with the intervertebral disc space C2/C3, in the left ventral aspect of the vertebral canal, heterogeneous hyperattenuating material is appreciated occupying approximately up to 20% of the cross-sectional area of the vertebral canal at the same level. The hyperattenuating material level C2/C3 is extending predominantly caudally over the cranial third of the vertebral body of C3. The dural tube level C2/C3 is deviated dorsally and to the left and is distorted.

Multiple intervertebral discs along the entire spine present variable degree of central mineralization.

T6 to T11 are malformed.

Multifocal mild spondylosis formation is seen along the thoracic and lumbar spine.

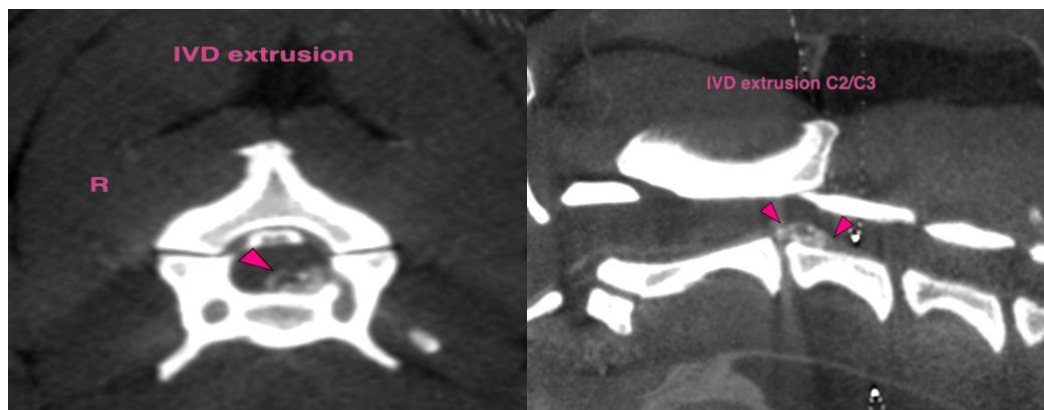
The remainder of the osseous and soft tissue structures of the spine present without pathological findings.

COMPUTED TOMOGRAPHIC DIAGNOSIS

- Intervertebral disc extrusion C2/C3 with compressive myelopathy
- Generalized chondroid disc degeneration along the cervical, thoracic and lumbar spine
- Congenital malformation T6 to T11
- Multifocal mild spondylosis formation thoracic a& lumbar spine

INTERPRETATION OF THE FINDINGS & FURTHER RECOMMENDATIONS

The intervertebral disc extrusion C2/C3 is a plausible explanation for the described pain in the cervical spine and may trigger the right front limb lameness.



The information and recommendations provided are based on the images presented by the



PATIENT

Biblia Montenegro

SPECIES

Canine

BREED

French Bulldog

SEX

Female

AGE

2 Years

WEIGHT

33 Pounds

INTERPRETED BY

Sebastian Schaub, DVM
Dr. med. vet. DipECVDI

IMAGING PERFORMED BY

Amarilys Cala

HOSPITAL NAME

Miami Springs AH

REFERRING VET

Dr. Andres Perez

INVOICE

37242

DATE

5/29/26

referring veterinarian/sonographer. No evaluation can be communicated regarding pathology that was not visible in the image/video clips provided.

Thank you for this referral. If the clinical or image interpretation does not parallel your findings or if I can be of any further assistance please contact me.

Sebastian Schaub, DVM, Dr. med. vet. DipECVDI
info@sonopath.com