



PATIENT

Meche Maria Bigay

SPECIES

Canine

BREED

Dachshund

SEX

Spayed Female

AGE

17 Years

WEIGHT

12.1 Pounds

INTERPRETED BY

Sebastian Schaub, DVM
Dr. med. vet. DipECVDI

IMAGING PERFORMED BY

José L. Alvarado Bruno,
CVT

HOSPITAL NAME

Veterinary Image
Center

REFERRING VET

Josean Colón, DVM

INVOICE

37239

DATE

5/28/26

PRESENTING CLINICAL SIGNS

History: Patient presented for CT scan for surgical plan. Patient presents hindlimbs paraparesis. Deep pain is present. History of IVD extrusion C5/6 on 2025.

Abnormal PE/Chem/CBC/UA Results: CBC --- RBC mild to moderate increased (9.23), HGB mild increased (20.6) CHEM --- AMYL mild decreased (395)

COMPUTED TOMOGRAPHIC STUDY OF THE CERVICAL, THORACIC AND LUMBAR SPINE

A high resolution pre- and post-contrast CT study of the entire spine is provided for review.

COMPUTED TOMOGRAPHIC FINDINGS

THE LAST RIB BEARING VERTEBRA IS COUNTED AS T13.

All intervertebral discs along the spine present variable degree of central mineralization.

The vertebral endplates C5/C6 present an irregular concave defect respectively and the respective intervertebral disc space is collapsed. The vertebral endplates C5/C6 present moderate spondylosis formation.

Level with the intervertebral disc space C6/C7, disc material is protruding into the vertebral canal, occupying approximately $\leq 15\%$ of the cross-sectional area of the vertebral canal at the same level.

The osseous and soft tissue structures of the cervical and thoracic spine reveal no additional abnormalities.

A vacuum phenomenon is seen in the intervertebral disc space L1/L2. Level with the intervertebral disc space L1/L2, heterogeneous hyperattenuating material is seen in the right ventrolateral aspect of the vertebral canal, occupying approximately up to 55% of the cross-sectional area of the vertebral canal at the same level. The hyperattenuating material level L1/L2 is extending cranially up to the level of the mid third of the vertebral body of L1 and caudally up to the level of the cranial vertebral endplate L2.

Level with the intervertebral disc space L4/L5, irregular hypoattenuating material is seen in the right ventral aspect of the vertebral canal, occupying approximately up to 10% of the cross-sectional area of the vertebral canal at the same level.

Multifocal along the lumbar spine, spondylosis formation is seen.

The remainder of the lumbar spine reveal no additional abnormalities.

COMPUTED TOMOGRAPHIC DIAGNOSIS

- Right sided intervertebral disc extrusion L1/L2 with compressive myelopathy
- History of ventral slot C5/C6 with secondary osseous remodeling of the respective vertebral endplates
- Intervertebral disc herniation L4/L5 without compressive myelopathy
- Generalized chondroid disc degeneration along the entire spine
- Spondylosis deformans

INTERPRETATION OF THE FINDINGS & FURTHER RECOMMENDATIONS



PATIENT

Meche Maria Bigay

SPECIES

Canine

BREED

Dachshund

SEX

Spayed Female

AGE

17 Years

WEIGHT

12.1 Pounds

INTERPRETED BY

Sebastian Schaub, DVM
Dr. med. vet. DipECVDI

IMAGING PERFORMED BY

José L. Alvarado Bruno,
CVT

HOSPITAL NAME

Veterinary Image
Center

REFERRING VET

Josean Colón, DVM

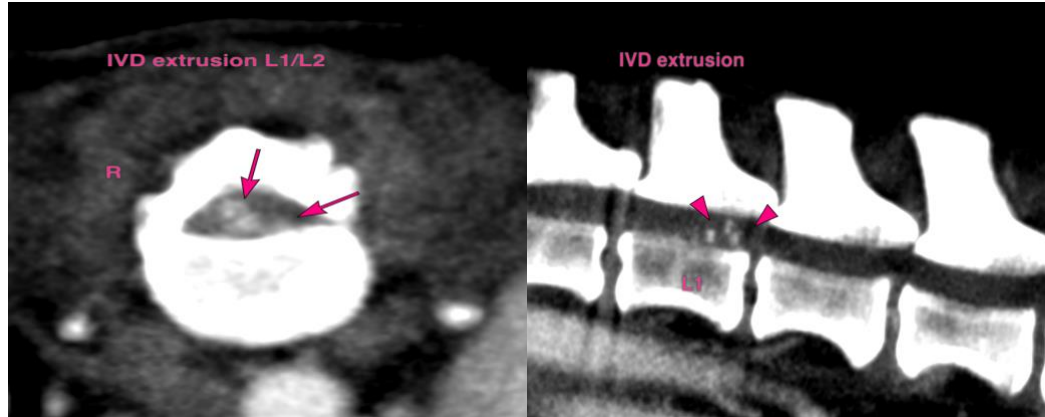
INVOICE

37239

DATE

5/28/26

The intervertebral disc extrusion L1/L2 is a plausible explanation for the presenting clinical signs – surgical decompression is considered beneficial.



The information and recommendations provided are based on the images presented by the referring veterinarian/sonographer. No evaluation can be communicated regarding pathology that was not visible in the image/video clips provided.

Thank you for this referral. If the clinical or image interpretation does not parallel your findings or if I can be of any further assistance please contact me.

Sebastian Schaub, DVM, Dr. med. vet. DipECVDI
info@sonopath.com