



**PATIENT**

Fiona Williams

**PRESENTING CLINICAL SIGNS**

Fiona is doing fine overall; a click was palpated in the left elbow and mild crepitus/clicking in both carpi at annual examination.  
Abnormal PE/Chem/CBC/UA Results: Normal labwork.

**SPECIES**

Canine

**COMPUTED TOMOGRAPHY OF THE FRONT LIMBS**

A high resolution plain CT study of the front limbs is provided for review.

**BREED**

Great Pyrenees Mix

**COMPUTED TOMOGRAPHIC FINDINGS**

The right & left elbow joint presents smooth osseous margins, and the medial coronoid process is well defined with a homogeneous density and physiological trabecular pattern. The joint space of both elbow joints is congruent.

**SEX**

FS

The periarticular bones of the right carpal joint present smooth osseous margins, unremarkable. At the medial and palmar aspect of the styloid process of the ulna, an isolated mineralized body, measuring up to 1.3 mm in size is seen respectively. No abnormalities of the soft tissues surrounding the right carpal joint are appreciated.

**AGE**

3 Years

At the lateropalmar aspect of the ulnar carpal bone, distal to the styloid process of the ulna, an irregular marginated, roundish body, measuring 5 x 3 x 6 mm in size.

**COMPUTED TOMOGRAPHIC DIAGNOSIS**

- Small metaplasia region of right styloid process of the ulna bilaterally, L>>R
- Normal elbow joints

**INTERPRETED BY**

Sebastian Schaub, DVM  
Dr. med. vet. DipECVDI

**INTERPRETATION OF THE FINDINGS & FURTHER RECOMMENDATIONS**

The mineralized body at the distal aspect of the left styloid process of the left carpal joint is most consistent with metaplasia or small calcinosis circumscripta. The odds for avulsion fracture are very low, due to lack of swelling or corresponding fragment bed. The clinical relevance of the small mineralization is questionable.

No abnormalities of the elbow joints are appreciated.

**HOSPITAL NAME**

Animal Health Care  
Denver

**REFERRING VET**

Cathryn Sayer

**INVOICE**

52158

**DATE**

5-28-22



**PATIENT**

Fiona Williams

**SPECIES**

Canine

**BREED**

Great Pyrenees Mix

**SEX**

FS

**AGE**

3 Years

**INTERPRETED BY**

Sebastian Schaub, DVM  
Dr. med. vet. DipECVDI

**HOSPITAL NAME**

Animal Health Care  
Denver

**REFERRING VET**

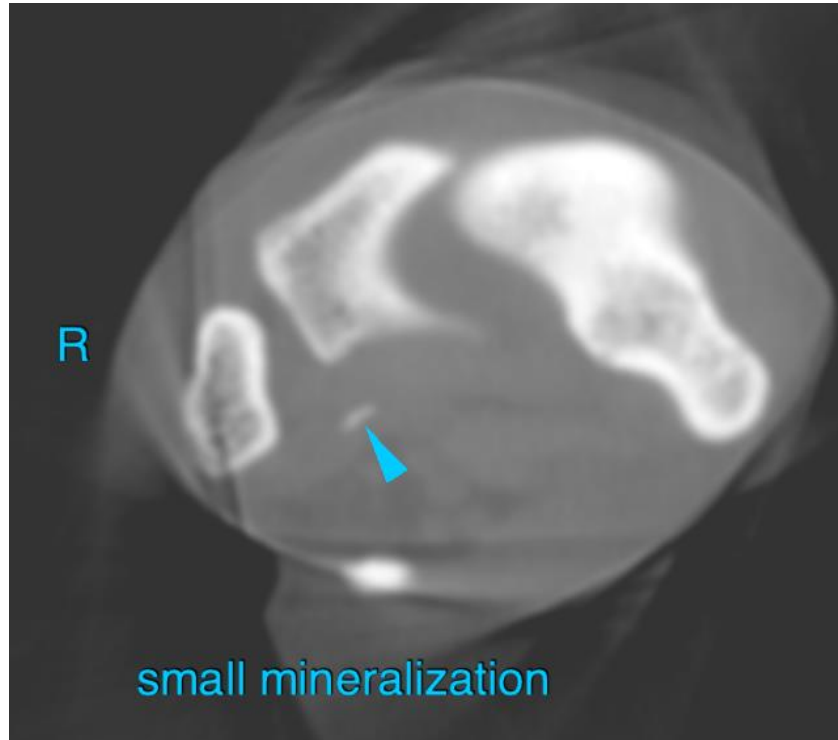
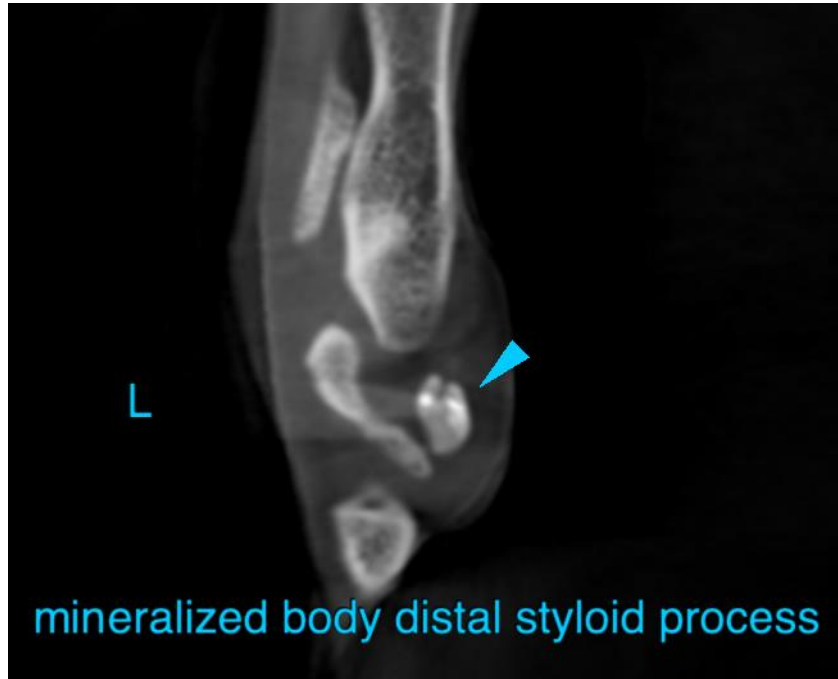
Cathryn Sayer

**INVOICE**

52158

**DATE**

5-28-22





**PATIENT**

Fiona Williams

The information and recommendations provided are based on the images presented by the referring veterinarian/sonographer. No evaluation can be communicated regarding pathology that was not visible in the image/video clips provided.

**SPECIES**

Canine

Thank you for this referral. If the clinical or image interpretation does not parallel your findings or if I can be of any further assistance please contact me.

**Sebastian Schaub**, Sebastian Schaub, DVM, Dr. med. vet. DipECVDI  
sebast.schaub@gmail.com

**BREED**

Great Pyrenees Mix

**SEX**

FS

**AGE**

3 Years

**INTERPRETED BY**

Sebastian Schaub, DVM  
Dr. med. vet. DipECVDI

**HOSPITAL NAME**

Animal Health Care  
Denver

**REFERRING VET**

Cathryn Sayer

**INVOICE**

52158

**DATE**

5-28-22