



PATIENT

Dakota Donohue

SPECIES

Canine

BREED

Labrador Retriever

SEX

FS

AGE

7Y, 7M

WEIGHT

77lbs

INTERPRETED BY

Sebastian Schaub, DVM
Dr. med. vet.
DipECVDD

IMAGING PERFORMED BY

Dr. Nick Hayes

HOSPITAL NAME

Gentle Doctor Animal
Hospital

REFERRING VET

Dr. Nick Hayes

INVOICE

75169

DATE

5-27-26

PRESENTING CLINICAL SIGNS

3-view Chest Radiographs performed to stage for a suspected soft tissue neoplasm over her right hip.

RADIOGRAPHIC STUDY OF THE THORAX

Radiographs of the thorax in three imaging planes are provided for review.

RADIOGRAPHIC FINDINGS

The VD view is moderately rotated to the left.

The surrounding bony structures are within normal limits.

The extrathoracic soft tissues present homogeneous without abnormalities.

The heart is of normal size and shape; there is no evidence of cardiac chamber or vascular enlargement. The pulmonary vasculature is within normal limits.

The cranial mediastinum presents the expected soft tissue opacity. The mediastinal width is less than twice the width of the vertebral column at the same level.

The trachea is normal in diameter and presents the anticipated course. The luminal outline of the trachea is smooth.

The bronchial tree presents with thin walls and tapers uniformly towards the periphery as expected.

The lung parenchyma presents the expected architecture and opacity; the intrapulmonary vascular branching is seen up to the third order lung vessels.

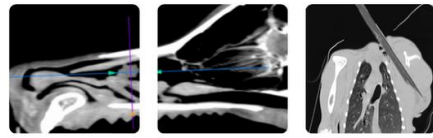
The diaphragm is well delineated with even surface and the expected mild cranial bulging of the diaphragmatic cupola.

RADIOGRAPHIC DIAGNOSIS

- Normal thorax

INTERPRETATION OF THE FINDINGS & FURTHER RECOMMENDATIONS

The radiographic study of the thorax reveals no abnormalities and is negative for metastatic disease.



PATIENT

Dakota Donohue

SPECIES

Canine

BREED

Labrador Retriever

SEX

FS

AGE

7Y, 7M

WEIGHT

77lbs

INTERPRETED BY

Sebastian Schaub, DVM
Dr. med. vet.
DipECVDI

IMAGING PERFORMED BY

Dr. Nick Hayes

HOSPITAL NAME

Gentle Doctor Animal
Hospital

REFERRING VET

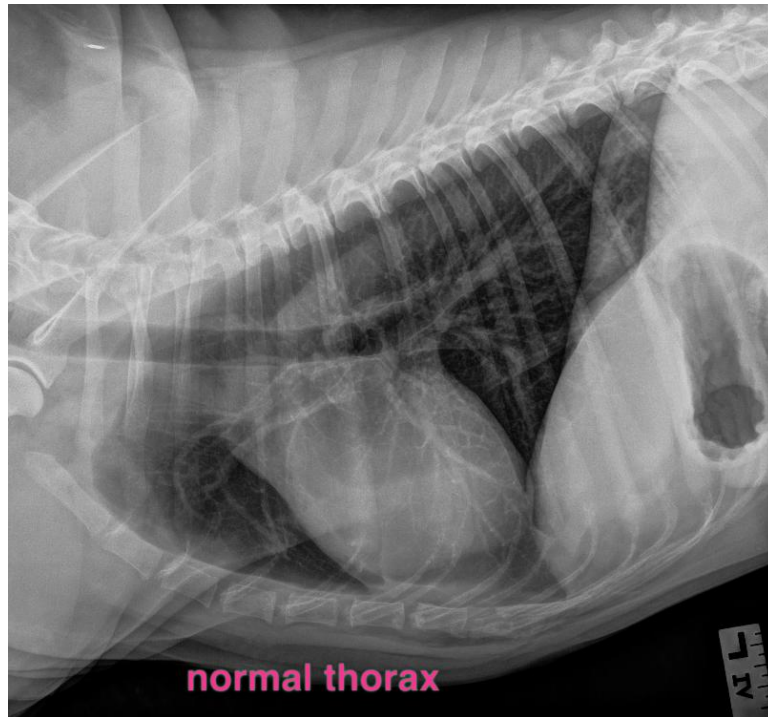
Dr. Nick Hayes

INVOICE

75169

DATE

5-27-26



The information and recommendations provided are based on the images presented by the referring veterinarian/sonographer. No evaluation can be communicated regarding pathology that was not visible in the image/video clips provided.

Thank you for this referral. If the clinical or image interpretation does not parallel your findings or if I can be of any further assistance please contact me.

Sebastian Schaub, Sebastian Schaub, DVM, Dr. med. vet. DipECVDI
info@sonopath.com