



PATIENT

Brandy Hopkins

SPECIES

Canine

BREED

Black Mouth Curr

SEX

Female Spayed

AGE

8Y

WEIGHT

30.0kg

INTERPRETED BY

Sebastian Schaub, DVM
Dr. med. vet.
DipECVDI

IMAGING PERFORMED BY

Victoria Bradshaw

HOSPITAL NAME

Gulf Shore Veterinary
Specialty Surgery

REFERRING VET

Dr. Byron Young DVM,
MS, DACVS

INVOICE

75166

DATE

5-27-26

PRESENTING CLINICAL SIGNS

Brandy was diagnosed with rostral mandibular ameloblastoma via biopsy performed by primary veterinarian in April 2026. Brandy was referred to Gulf Shore for CT imaging of the lesion for surgical planning.

COMPUTED TOMOGRAPHY OF THE SKULL

A high resolution pre- and post-contrast CT study of the skull is provided for review.

COMPUTED TOMOGRAPHIC FINDINGS

The dorsal parts of the neurocranium are cropped by the field of view.

Triadan 301, 302, 401-404 are absent. A supernumerary triadan 205 is seen.

The rostral segment of the body of the right mandible, level with absent triadan 401 to 406, an ill-defined zone with permeative osteolysis and amorphous periosteal new bone formation is seen.

The nasal cavity presents the expected aerated spaces between thin & even conchae and turbinates with smooth mucosal lining. Protruding from the roof of the nasopharynx, a small polypoid lesion is appreciated; measuring 5 mm in diameter.

Both temporomandibular joints present congruent joint spaces with even subchondral bone surfaces and are considered within normal limits.

Both tympanic bullae are aerated, the mucosal lining is not seen, the bony wall is smooth and thin. In the most medial aspect of the right external ear canal, a small amount of non-contrast enhancing soft tissue material is seen.

The brain presents no deviation from normal anatomy and symmetry. The brain parenchyma is homogeneous and within normal limits for attenuation and distribution of contrast enhancement. The ventricular system is non-dilated and symmetric.

The submandibular and medial retropharyngeal lymph nodes are small and elongated with a normal short-to-long-axis-ratio is < 0.5, the attenuation and contrast enhancement pattern is uniform.

COMPUTED TOMOGRAPHIC DIAGNOSIS

- History of ameloblastoma rostral segment body of right mandible
- Small polypoid nasopharyngeal lesion
- Absent triadan 301, 302, 401-404
- Supernumerary triadan 205
- Mild amount of cerumen in right external ear canal

INTERPRETATION OF THE FINDINGS & FURTHER RECOMMENDATIONS

The monostotic aggressive mixed osteolytic and osteoproliferative bone lesion of the body of the right mandible is fitting the history of ameloblastoma. Complete surgical resection via rostral mandibulectomy appears feasible – potential osteotomy lines are distal to triadan 406 or 407 and mesial to triadan 304.

The small polypoid lesion of the roof of the nasopharynx is considered as an incidental finding and can present a 'real' polyp, small mucus or salivary cyst/Thornwaldt like cyst.



PATIENT

Brandy Hopkins

SPECIES

Canine

BREED

Black Mouth Curr

SEX

Female Spayed

AGE

8Y

WEIGHT

30.0kg

INTERPRETED BY

Sebastian Schaub, DVM
Dr. med. vet.
DipECVDI

IMAGING PERFORMED BY

Victoria Bradshaw

HOSPITAL NAME

Gulf Shore Veterinary
Specialty Surgery

REFERRING VET

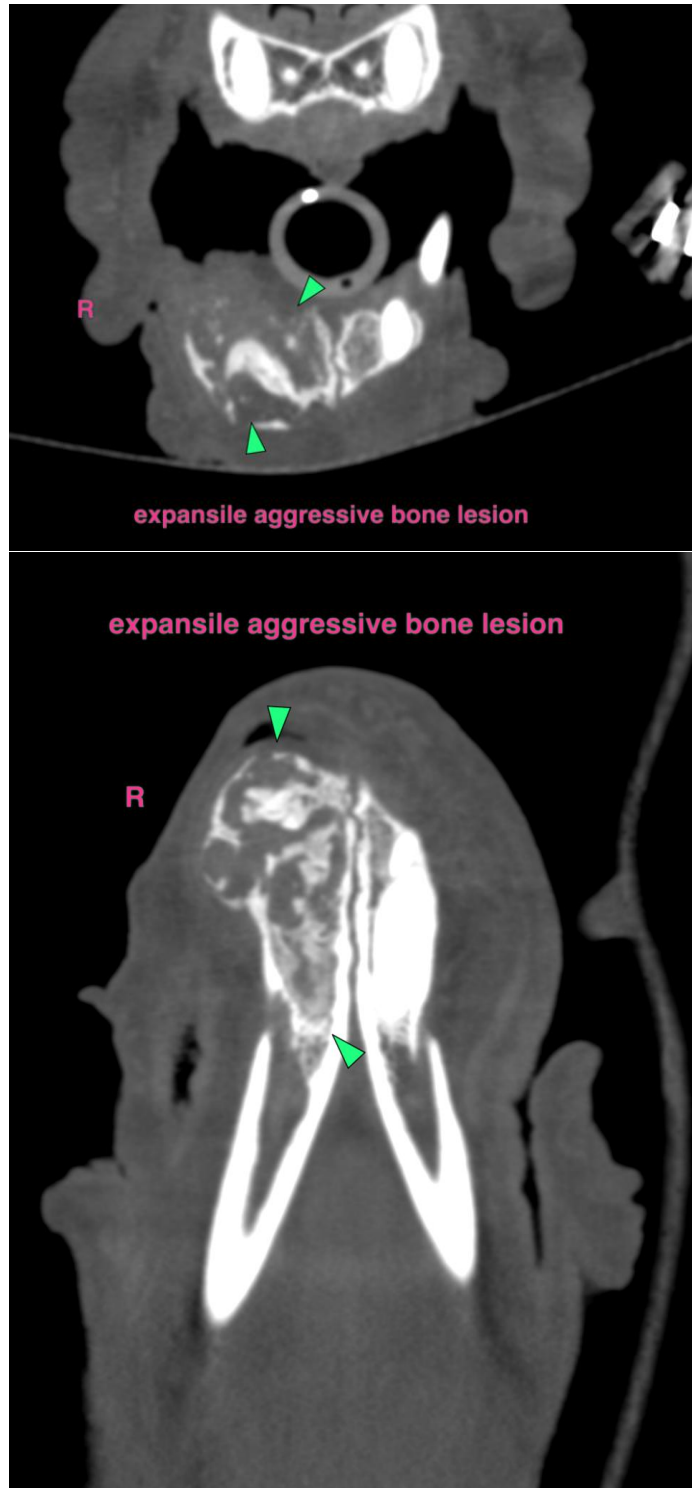
Dr. Byron Young DVM,
MS, DACVS

INVOICE

75166

DATE

5-27-26





PATIENT

Brandy Hopkins

SPECIES

Canine

BREED

Black Mouth Curr

SEX

Female Spayed

AGE

8Y

WEIGHT

30.0kg

INTERPRETED BY

Sebastian Schaub, DVM
Dr. med. vet.
DipECVDI

IMAGING PERFORMED BY

Victoria Bradshaw

HOSPITAL NAME

Gulf Shore Veterinary
Specialty Surgery

REFERRING VET

Dr. Byron Young DVM,
MS, DACVS

INVOICE

75166

DATE

5-27-26

The information and recommendations provided are based on the images presented by the referring veterinarian/sonographer. No evaluation can be communicated regarding pathology that was not visible in the image/video clips provided.

Thank you for this referral. If the clinical or image interpretation does not parallel your findings or if I can be of any further assistance please contact me.

Sebastian Schaub, Sebastian Schaub, DVM, Dr. med. vet. DipECVDI
info@sonopath.com