



PATIENT PRESENTING CLINICAL SIGNS

Teddy Barnhart History: Pet presented for a dental cleaning and nasal lacrimal flush
Abnormal PE/Chem/CBC/UA Results:

SPECIES COMPUTED TOMOGRAPHIC STUDY OF THE SKULL

Canine A high-resolution plain CT study of the viscerocranium is provided for review.

COMPUTED TOMOGRAPHIC FINDINGS

BREED

Havanese Triadan 105, 107, 108, 205, 301, 311, 401, 402 and 411 are absent. A significant amount of mineralized material is attached to the crowns of the maxillary & mandibular molar teeth. Triadan 110, 209, 210, 310 and 410 present a significant widening of the periodontal space. The distal root of triadan 406 presents a moderate periapical widening of the periodontal space. The remainder of the dentition present evidence of mild horizontal bone of the alveolar bone.

SEX

Neutered Male The nasal cavity presents the expected aerated spaces between thin & even conchae and turbinates with smooth mucosal lining.

AGE

11 Years The volume of the left ocular bulb is significantly decreased and presents central heterogeneous mineralization – suspect the lens.

COMPUTED TOMOGRAPHIC DIAGNOSIS

INTERPRETED BY

Sebastian Schaub,
DVM Dr. med. vet.
DipECVDI

- Advanced periodontal disease 110, 209, 210, 310 and 410
- Periapical granuloma 406
- Generalized mild to moderate periodontal disease of the remaining disease
- Generalized dental tartar
- Absent triadan 105, 107, 108, 205, 301, 311, 401, 402 and 411
- Left sided microphthalmos with dystrophic lenticular mineralization – possible chronic endophthalmitis, congenital malformation or preceding blunt ocular trauma

HOSPITAL NAME

Cranberry Holistic Pet
Care

INTERPRETATION OF THE FINDINGS & FURTHER RECOMMENDATIONS

The findings are consistent with generalized periodontal disease, most advanced triadan **110, 209, 210, 310, 406 and 410. A complete dental workup has already been performed, regarding the history.**

REFERRING VET

Cynthia Maro

INVOICE

15791

DATE

5/27/22



PATIENT

Teddy Barnhart

SPECIES

Canine

BREED

Havanese

SEX

Neutered Male

AGE

11 Years

INTERPRETED BY

Sebastian Schaub,
DVM Dr. med. vet.
DipECVDI

HOSPITAL NAME

Cranberry Holistic Pet
Care

REFERRING VET

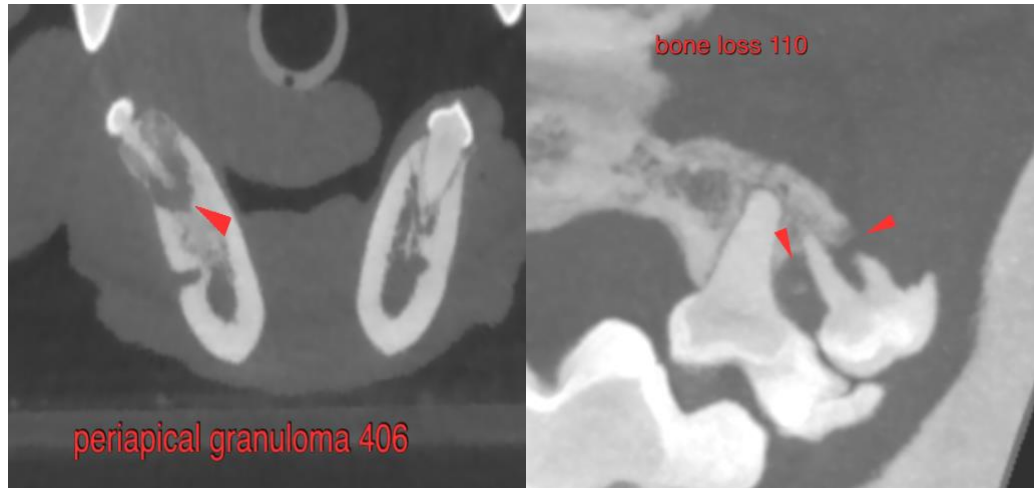
Cynthia Maro

INVOICE

15791

DATE

5/27/22



The information and recommendations provided are based on the images presented by the referring veterinarian/sonographer. No evaluation can be communicated regarding pathology that was not visible in the image/video clips provided.

Thank you for this referral. If the clinical or image interpretation does not parallel your findings or if I can be of any further assistance please contact me.

Sebastian Schaub, Sebastian Schaub, DVM, Dr. med. vet. DipECVDI
sebast.schaub@gmail.com