



PATIENT

Yogi Jackson

SPECIES

Canine

BREED

Cavoodle

SEX

FN

AGE

6

WEIGHT

6

INTERPRETED BY

Sebastian Schaub, DVM
Dr. med. vet.
DipECVDI

IMAGING PERFORMED BY

Eamon

HOSPITAL NAME

Belconnen Veterinary
Centre

REFERRING VET

Eamon

INVOICE

75110

DATE

5-25-26

PRESENTING CLINICAL SIGNS

hbc presented for assessment metatarsal fx
- noted pneumothorax

Abnormal PE/Chem/CBC/UA Results: cbc/chem wl

COMPUTED TOMOGRAPHY OF THE THORAX AND ABDOMEN

A pre- and post-contrast CT study of the thorax and abdomen in a bone, lung and soft tissue reconstruction is provided for review.

COMPUTED TOMOGRAPHIC FINDINGS

Thorax

The bony and surrounding soft tissue structures are within normal limits – but multiple motion artefacts

In the pleural cavity, L>R, a small to moderate amount of free gas is seen; the lung lobes are retracted from the thoracic wall.

The sternal, cranial mediastinal and tracheobronchial lymph nodes are small elongated with a normal short-to-long-axis-ratio is < 0.5, the attenuation and contrast enhancement pattern is uniform and considered within normal limits.

The left atrium and left atrial auricular appendage are prominent.

The bronchial tree presents with regular branching and tapers uniformly towards the periphery as expected, the bronchial walls are thin and smooth. The bronchus-to-artery ratio is within normal limits.

The lung parenchyma presents the expected architecture and attenuation behavior.

Small incidental gas pockets are seen within the esophageal lumen; there is no evidence of abnormal dilation.

Abdomen

The serosal fat presents normal attenuation behavior. There is no evidence of peritoneal effusion or peritonitis.

Both kidneys present within normal limits for size, shape and organ architecture. After contrast administration a bilaterally symmetric and uniform nephro- and pyelogram is noted – but a well-defined, roundish parenchymal filling defect in the caudal pole of the left kidney.

The adrenal glands are within normal limits for size, shape and organ architecture.

Both liver and spleen present with normal shape, even surface, uniformly attenuating parenchyma and homogeneous contrast enhancement, unremarkable.

The pancreas is evenly contoured; the pancreatic parenchyma is homogeneous and presents uniform contrast enhancement.

The position, delineation, wall and content of the gastrointestinal tract are considered within normal limits throughout.

The bony and surrounding soft tissue structures reveal no abnormalities.



PATIENT

Yogi Jackson

SPECIES

Canine

BREED

Cavoodle

SEX

FN

AGE

6

WEIGHT

6

INTERPRETED BY

Sebastian Schaub, DVM
Dr. med. vet.
DipECVDP

IMAGING PERFORMED BY

Eamon

HOSPITAL NAME

Belconnen Veterinary
Centre

REFERRING VET

Eamon

INVOICE

75110

DATE

5-25-26

COMPUTED TOMOGRAPHIC DIAGNOSIS

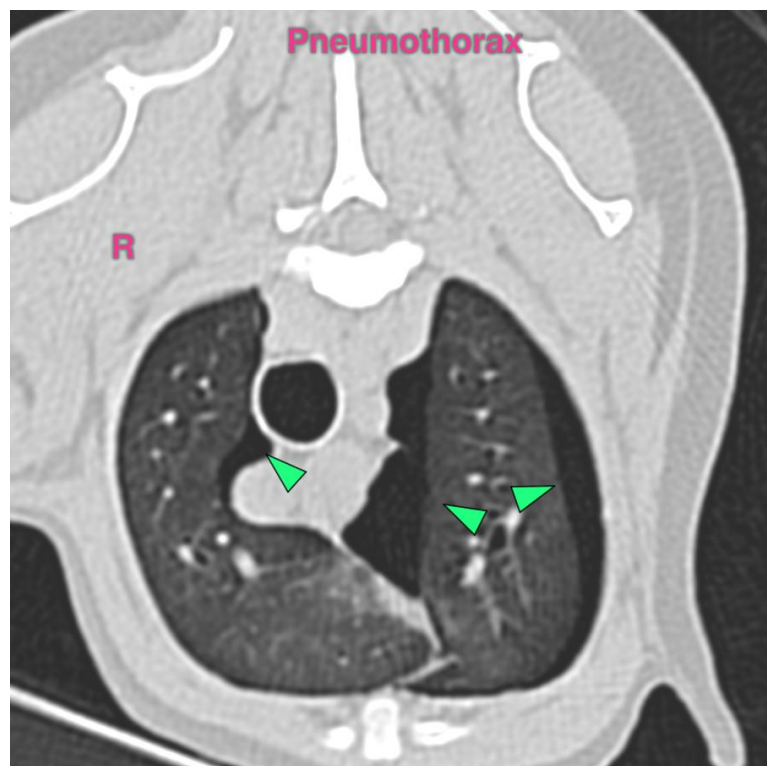
- Pneumothorax, L>R
- Prominent left atrium
- Simple solitary renal cyst, left kidney

INTERPRETATION OF THE FINDINGS & FURTHER RECOMMENDATIONS

In combination with the history, the CT study reveals a traumatic pneumothorax – commonly resolves spontaneously within the next couple of days.

The prominent left atrium can be indicative for underlying mitral valve disease – correlate with findings of the clinical examination.

No additional clinically relevant abnormalities are appreciated.





PATIENT

Yogi Jackson

SPECIES

Canine

BREED

Cavoodle

SEX

FN

AGE

6

WEIGHT

6

INTERPRETED BY

Sebastian Schaub, DVM
Dr. med. vet.
DipECVDI

IMAGING PERFORMED BY

Eamon

HOSPITAL NAME

Belconnen Veterinary
Centre

REFERRING VET

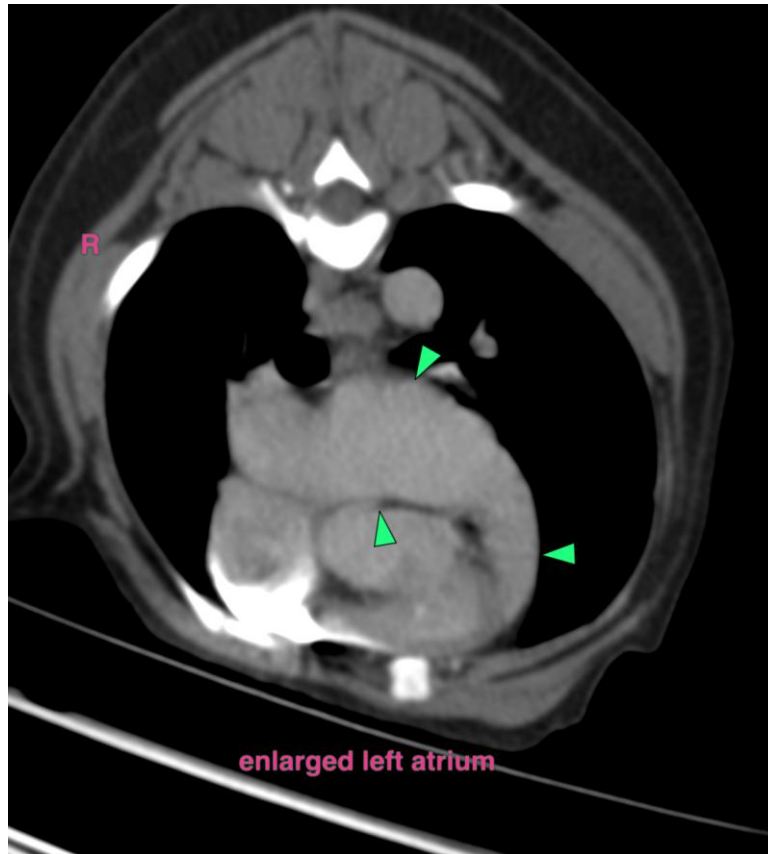Eamon

INVOICE

75110

DATE

5-25-26



The information and recommendations provided are based on the images presented by the referring veterinarian/sonographer. No evaluation can be communicated regarding pathology that was not visible in the image/video clips provided.

Thank you for this referral. If the clinical or image interpretation does not parallel your findings or if I can be of any further assistance please contact me.

Sebastian Schaub, Sebastian Schaub, DVM, Dr. med. vet. DipECVDI
info@sonopath.com