

PATIENT

Lucca Durand

SPECIES

Canine

BREED

Toy Poodle

SEX

Male

AGE

7 Months

WEIGHT

3.4 Pounds

INTERPRETED BY

Sebastian Schaub, DVM
Dr. med. vet. DipECVCI

IMAGING PERFORMED BY

Monika Salgado

HOSPITAL NAME

Westchester AH

REFERRING VET

Dr. Randy Dominguez

INVOICE

37202

DATE

5/22/26

PRESENTING CLINICAL SIGNS

History: Presented referred from GILS (Dr. Sanchez) with a history of left T.L valgus deformity. X-rays revealed a severe bone problem of unknown cause in the left physis and metaphysis of the left Radio and Ulna. Abnormal PE/Chem/CBC/UA Results: Unremarkable

COMPUTED TOMOGRAPHIC STUDY OF THE CARPAL JOINTS

A high resolution pre- and post-contrast CT study of the carpal joints is provided for review.

COMPUTED TOMOGRAPHIC FINDINGS

The growth plates are age related open.

The distal epiphysis of the left radius and ulna are oriented cranially. The distal physis of the left radius & ulna present an ill-defined, discontinuity with a fragment of the metaphysis respectively.

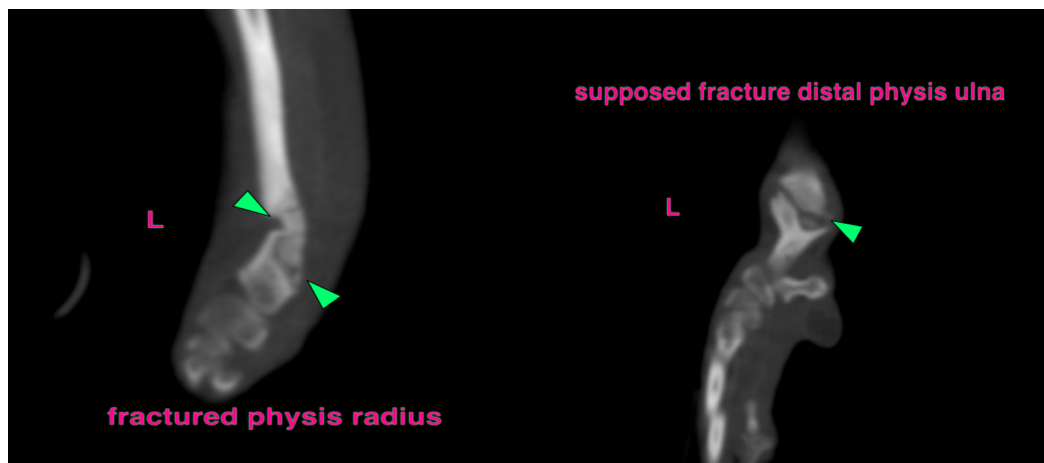
The osseous and surrounding soft tissue structures of the carpus bilaterally are within normal limits.

COMPUTED TOMOGRAPHIC DIAGNOSIS

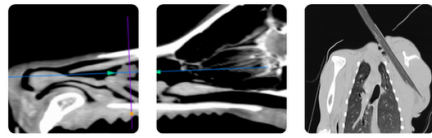
- Chronic Salter Harris type 2 fracture distal physis of the left radius and ulna, secondary cranial angulation of the distal epiphysis
- Normal carpus bilaterally

INTERPRETATION OF THE FINDINGS & FURTHER RECOMMENDATIONS

The findings are consistent with a chronic Salter-Harris type II fracture with secondary cranial angulation of the distal fragments; periosteal support may have provided stabilization. Surgical management is recommended. Irreversible damage to the distal growth plate of the left radius is likely; however, in this 7-month-old small-breed dog, growth is expected to be nearly complete within the next 1-2 months, with minimal additional longitudinal growth anticipated.



The information and recommendations provided are based on the images presented by the referring veterinarian/sonographer. No evaluation can be communicated regarding pathology that was not visible in the image/video clips provided.



PATIENT

Lucca Durand

SPECIES

Canine

BREED

Toy Poodle

SEX

Male

AGE

7 Months

WEIGHT

3.4 Pounds

INTERPRETED BY

Sebastian Schaub, DVM
Dr. med. vet. DipECVDI

**IMAGING
PERFORMED BY**

Monika Salgado

HOSPITAL NAME

Westchester AH

REFERRING VET

Dr. Randy Dominguez

INVOICE

37202

DATE

5/22/26

Thank you for this referral. If the clinical or image interpretation does not parallel your findings or if I can be of any further assistance please contact me.

Sebastian Schaub, DVM, Dr. med. vet. DipECVDI
info@sonopath.com