



## PATIENT

The Dude Laurin

## SPECIES

K9

## BREED

Bichon Poodle

## SEX

Male

## AGE

12Y

## WEIGHT

6.4kg

## INTERPRETED BY

Sebastian Schaub, DVM  
Dr. med. vet.  
DipECVDI

## IMAGING PERFORMED BY

Ali

## HOSPITAL NAME

Green Dog Dental and  
Wellness

## REFERRING VET

Dr. Sherry

## INVOICE

75094

## DATE

5-21-26

## PRESENTING CLINICAL SIGNS

anal gland sac identified . Pre surgical chest rads

## RADIOGRAPHIC STUDY OF THE THORAX

Radiographs of the thorax in three imaging planes are provided for review.

## RADIOGRAPHIC FINDINGS

The surrounding bony structures are within normal limits.

The extrathoracic soft tissues present homogeneous without abnormalities.

The heart is of normal size and shape; there is no evidence of cardiac chamber or vascular enlargement. The pulmonary vasculature is within normal limits.

The cranial mediastinum presents the expected soft tissue opacity. The mediastinal width is less than twice the width of the vertebral column at the same level.

The trachea is normal in diameter and presents the anticipated course. The luminal outline of the trachea is smooth.

The bronchial tree presents with thin walls and tapers uniformly towards the periphery as expected.

The lung parenchyma presents the expected architecture and opacity; the intrapulmonary vascular branching is seen up to the third order lung vessels.

The diaphragm is well delineated with even surface and the expected mild cranial bulging of the diaphragmatic cupola.

In the pictured parts of the abdomen, branching mineralization of the hepatic parenchyma is appreciated.

## RADIOGRAPHIC DIAGNOSIS

- Mineralization of the intrahepatic biliary tree - commonly incidental
- No evidence of pulmonary metastatic disease

## INTERPRETATION OF THE FINDINGS & FURTHER RECOMMENDATIONS

The radiographic study is negative for pulmonary metastatic disease.



## PATIENT

The Dude Laurin

## SPECIES

K9

## BREED

Bichon Poodle

## SEX

Male

## AGE

12Y

## WEIGHT

6.4kg

## INTERPRETED BY

Sebastian Schaub, DVM  
Dr. med. vet.  
DipECVDI

## IMAGING PERFORMED BY

Ali

## HOSPITAL NAME

Green Dog Dental and  
Wellness

## REFERRING VET

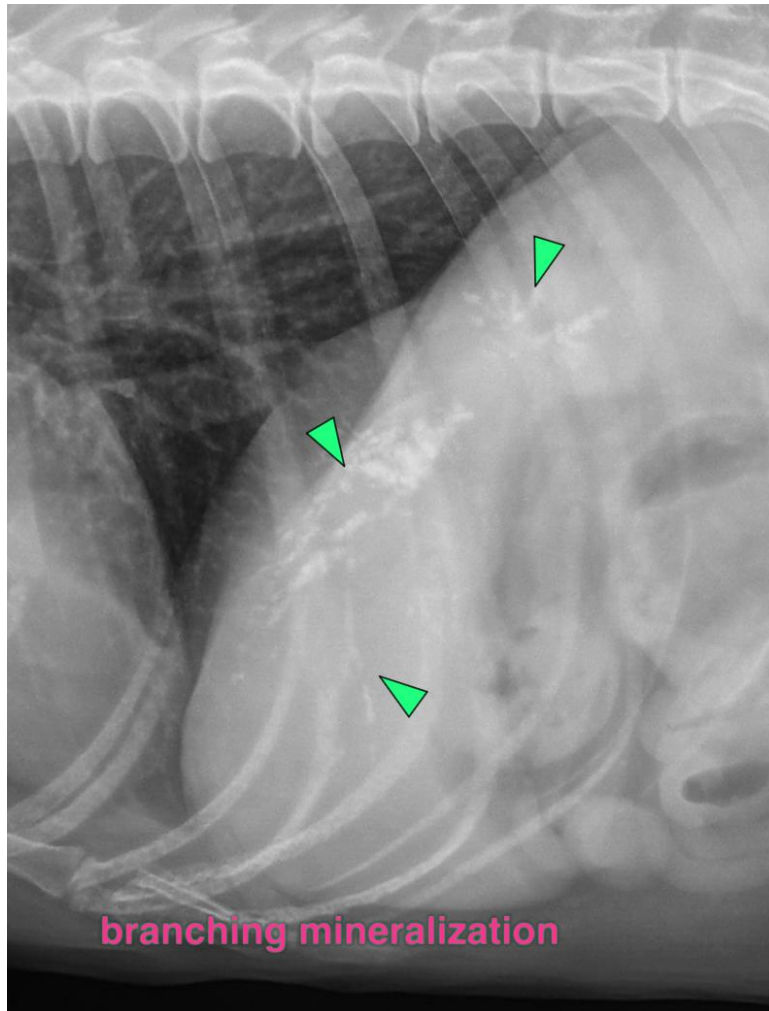
Dr. Sherry

## INVOICE

75094

## DATE

5-21-26



The information and recommendations provided are based on the images presented by the referring veterinarian/sonographer. No evaluation can be communicated regarding pathology that was not visible in the image/video clips provided.

Thank you for this referral. If the clinical or image interpretation does not parallel your findings or if I can be of any further assistance please contact me.

**Sebastian Schaub**, Sebastian Schaub, DVM, Dr. med. vet. DipECVDI  
[info@sonopath.com](mailto:info@sonopath.com)