



**PATIENT**

Picoh Inglis

**PRESENTING CLINICAL SIGNS**

Patient ate a tampon on 04/28/22 that was vomited out on 04/30/22. Vomiting on and off since. Not eating, lethargic. R/O FB vs pyometra vs any other abnormalities. Not spayed, O states last heat 6 months ago. No vaginal discharge. No fever or blood infections. Abnormal PE/Chem/CBC/UA Results: Blood work results attached

**SPECIES**

Canine

**RADIOGRAPHIC STUDY OF THE ABDOMEN**

Radiographs of the abdomen three imaging planes are provided for review.

**BREED**

Jack Russell Terrier

**RADIOGRAPHIC FINDINGS**

The surrounding bony structures are within normal limits.

No abnormalities of the extraabdominal soft tissues are noted. The abdominal wall is smooth and thin.

**SEX**

Female

The serosal detail is maintained throughout the peritoneal and retroperitoneal space.

The liver is appropriate in position, size and presents uniform opacity.

**AGE**

9 Years

The splenic head is in the anticipated position and within normal limits for size and opacity. The splenic body and tail are considered normal for position, size, shape and opacity.

Both kidneys are seen and present with normal size, shape, delineation and opacity. The urinary bladder is in its anticipated position. No radiopaque calculi are noted throughout the upper and lower urinary tract.

**INTERPRETED BY**

Sebastian Schaub, DVM  
Dr. med. vet. DipECVDI

The stomach is in its anticipated position and is empty.

In the left mid ventral abdomen, a moderately dilated small intestinal loop is appreciated, containing foamy soft tissue material and nearly homogenous soft tissue material. The dilated small intestinal loops results in presence of two populations of small intestinal loops

**HOSPITAL NAME**

Truscott Animal  
Hospital

The colon is seen in the expected position and is nearly empty.

**RADIOGRAPHIC DIAGNOSIS**

- Segmental small intestinal mechanical obstruction

**REFERRING VET**

Medhat Meawad

**INTERPRETATION OF THE FINDINGS & FURTHER RECOMMENDATIONS**

The radiographic study is consistent with small intestinal mechanical obstruction – possibly tampon or fabric material (intussusception). Surgical intervention is recommended.

**INVOICE**

51867

**DATE**

5-2-22



**PATIENT**

PicoH Inglis

**SPECIES**

Canine

**BREED**

Jack Russell Terrier

**SEX**

Female

**AGE**

9 Years

**INTERPRETED BY**

Sebastian Schaub, DVM  
Dr. med. vet. DipECVDI

**HOSPITAL NAME**

Truscott Animal  
Hospital

**REFERRING VET**

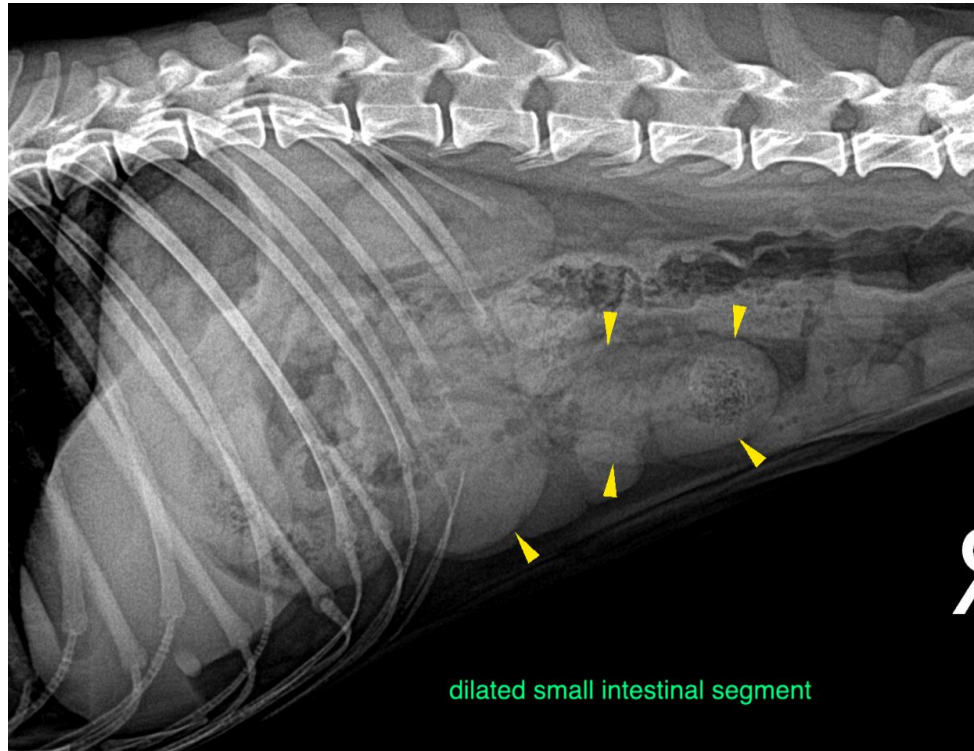
Medhat Meawad

**INVOICE**

51867

**DATE**

5-2-22



The information and recommendations provided are based on the images presented by the referring veterinarian/sonographer. No evaluation can be communicated regarding pathology that was not visible in the image/video clips provided.

Thank you for this referral. If the clinical or image interpretation does not parallel your findings or if I can be of any further assistance please contact me.

**Sebastian Schaub**, Sebastian Schaub, DVM, Dr. med. vet. DipECVDI  
sebast.schaub@gmail.com