



PATIENT

Jagger Sevel

PRESENTING CLINICAL SIGNS

Left pelvic limb lameness progressive. No craniocaudal stifle instability palpable but significant swelling/effusion evident on radiographs.
Abnormal PE/Chem/CBC/UA Results: Effusive left stifle with suspected joint centred tumor.

SPECIES

Canine

COMPUTED TOMOGRAPHY OF THE LEFT STIFLE JOINT

A pre- and post-contrast CT study of the left stifle joint is provided for review.

BREED

Bernese Mountain
Dog

COMPUTED TOMOGRAPHIC FINDINGS

The left stifle joint presents with a significant circumferential intracapsular soft tissue swelling with a multicameral appearance, most accentuated at the cranial aspect of the left stifle joint. The articular swelling is extending distally along the outpouching of the synovial capsule following the long digital extensor muscle post-contrast administration, heterogeneous mild contrast enhancement of the periarticular swelling is appreciated. Multifocal irregular moth eaten osteolytic lesions and depression of the cortex of the femoral condyles and the femoral trochlear ridges are appreciated. The tibial plateau presents with small osteolytic of the cortex.

SEX

MN

The popliteal lymph node is small, unremarkable.

AGE

6.5

COMPUTED TOMOGRAPHIC DIAGNOSIS

- Marked articular swelling left stifle joint with multicameral appearance of the synovial lining and polyostotic aggressive osteolytic lesions of the left femur and tibia

INTERPRETED BY

Sebastian Schaub, DVM
Dr. med. vet. DipECVDI

INTERPRETATION OF THE FINDINGS & FURTHER RECOMMENDATIONS

The swelling of the left stifle joint presents with aggressive imaging features, supporting the diagnosis of articular soft tissue neoplasm. Differentials include synovial cell sarcoma, histiocytic sarcoma, fibrosarcoma, myxosarcoma, other. FNA sampling ± biopsy of the left stifle joint can be used to confirm the diagnosis.

HOSPITAL NAME

Animal Health
Partners

REFERRING VET

Debbie Reynolds

INVOICE

52183

DATE

5-16-22



PATIENT

Jagger Sevel

SPECIES

Canine

BREED

Bernese Mountain
Dog

SEX

MN

AGE

6.5

INTERPRETED BY

Sebastian Schaub, DVM
Dr. med. vet. DipECVDI

HOSPITAL NAME

Animal Health
Partners

REFERRING VET

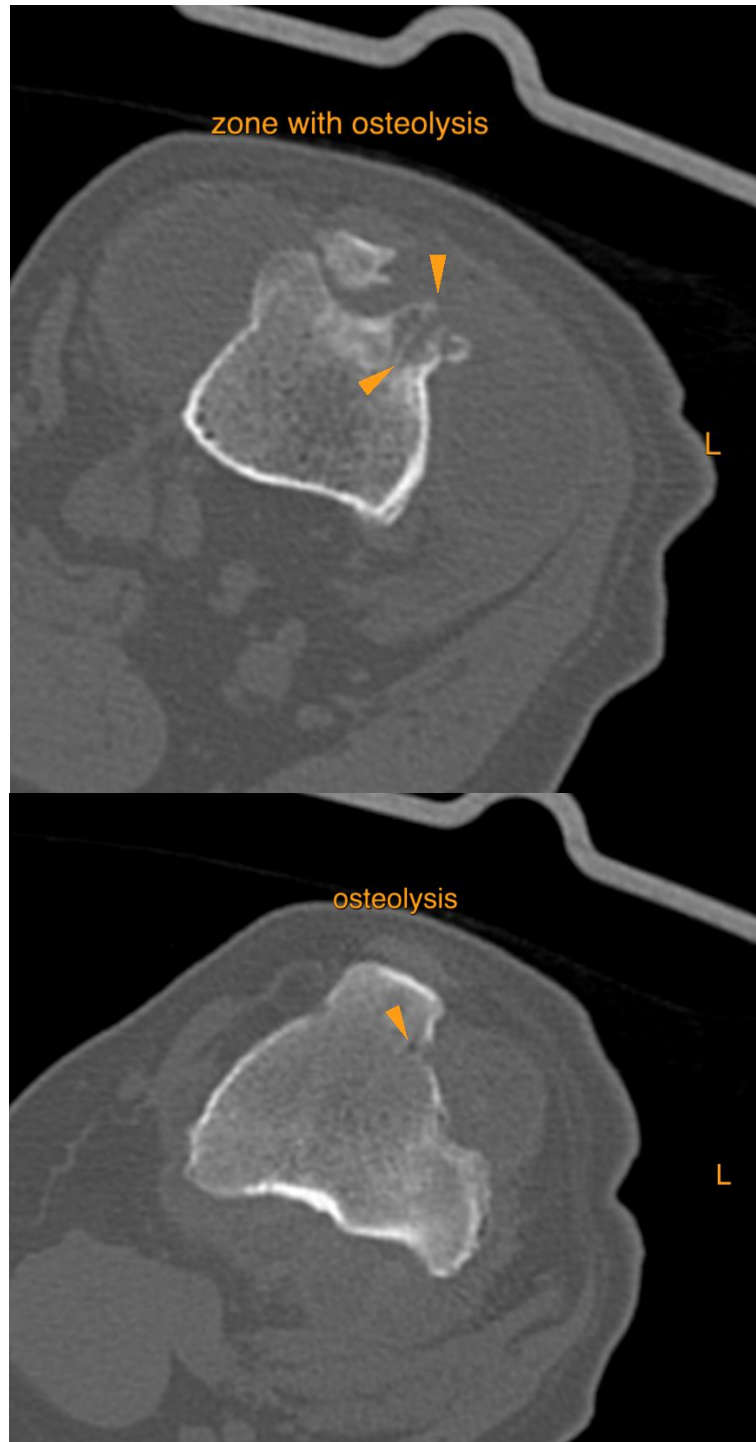
Debbie Reynolds

INVOICE

52183

DATE

5-16-22





PATIENT

Jagger Sevel

SPECIES

Canine

BREED

Bernese Mountain
Dog

SEX

MN

AGE

6.5

INTERPRETED BY

Sebastian Schaub, DVM
Dr. med. vet. DipECVDI

HOSPITAL NAME

Animal Health
Partners

REFERRING VET

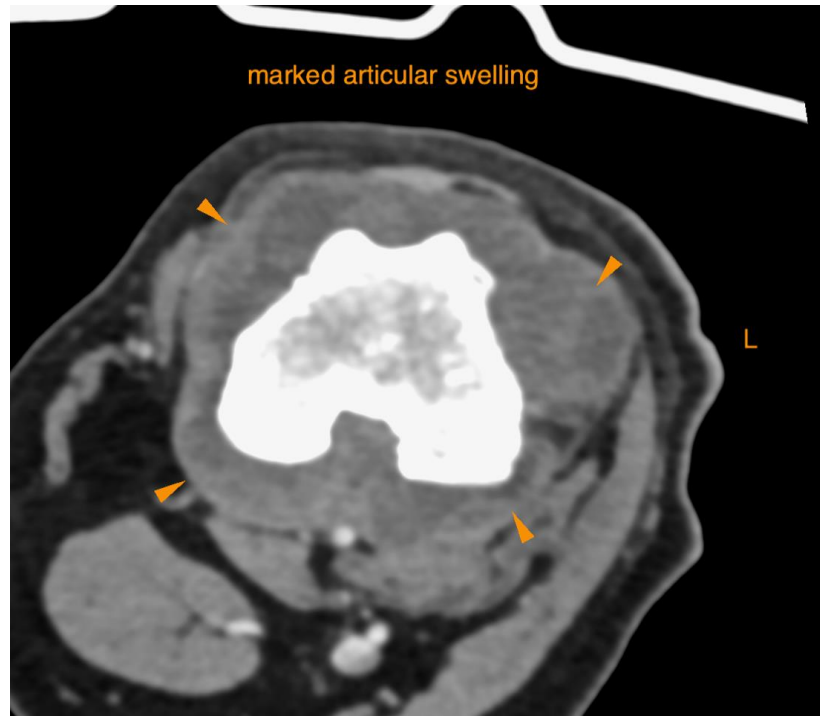Debbie Reynolds

INVOICE

52183

DATE

5-16-22



The information and recommendations provided are based on the images presented by the referring veterinarian/sonographer. No evaluation can be communicated regarding pathology that was not visible in the image/video clips provided.

Thank you for this referral. If the clinical or image interpretation does not parallel your findings or if I can be of any further assistance please contact me.

Sebastian Schaub, Sebastian Schaub, DVM, Dr. med. vet. DipECVDI
sebast.schaub@gmail.com