PATIENT
Doris Madden

SPECIES
Feline

BREED
DLH

SEX
Neutered Male

AGE
10 Years

WEIGHT
5.96 kg

INTERPRETED BY
Sebastian Schaub, DVM
Dr. med. vet. DipECVDI

IMAGING PERFORMED BY
BN

HOSPITAL NAME
Bridgwater Veterinary Hospital and Wellness Centre

REFERRING VET
Dr. Najot Brar

INVOICE
16307

DATE
05/15/26

PRESENTING CLINICAL SIGNS

Previous CT #1773858126 March 18/26. repeat CT today as previous results were inconclusive. No epistaxis since. but still sneezes 3-4 times weekly.

COMPUTED TOMOGRAPHIC STUDY OF THE SKULL

A high resolution pre- and post-contrast CT study of the skull is provided for review.

COMPUTED TOMOGRAPHIC FINDINGS

Triadan 303 is absent.

Mild focal consolidation of the nasal cavity is appreciated along with localized mild mucosal thickening.

Both temporomandibular joints present congruent joint spaces with even subchondral bone surfaces and are considered within normal limits.

In the left tympanic bulla, a very small amount of fluid attenuating material is attached to the wall; the osseous wall of the left tympanic bulla is mildly thickened and smooth. The external ear canals are within normal limits.

The brain presents no deviation from normal anatomy and symmetry. The brain parenchyma is homogeneous and within normal limits for attenuation and distribution of contrast enhancement. The ventricular system is non-dilated and symmetric.

The submandibular and medial retropharyngeal lymph nodes are small and elongated with a normal short-to-long-axis-ratio is < 0.5, the attenuation and contrast enhancement pattern is uniform.

COMPUTED TOMOGRAPHIC DIAGNOSIS

- Right sided mild rhinitis – regressive
- Left sided chronic mild otitis media

INTERPRETATION OF THE FINDINGS & FURTHER RECOMMENDATIONS

The findings are regressive in comparison to the preceding CT series, supporting the diagnosis of rhinitis – in feline patients' primary viral origin is likely. Due to the unilateral distribution of the rhinitis, nasal foreign body can be a potential, but in regards to the chronicity of clinical signs I would expect a more destructive pattern.

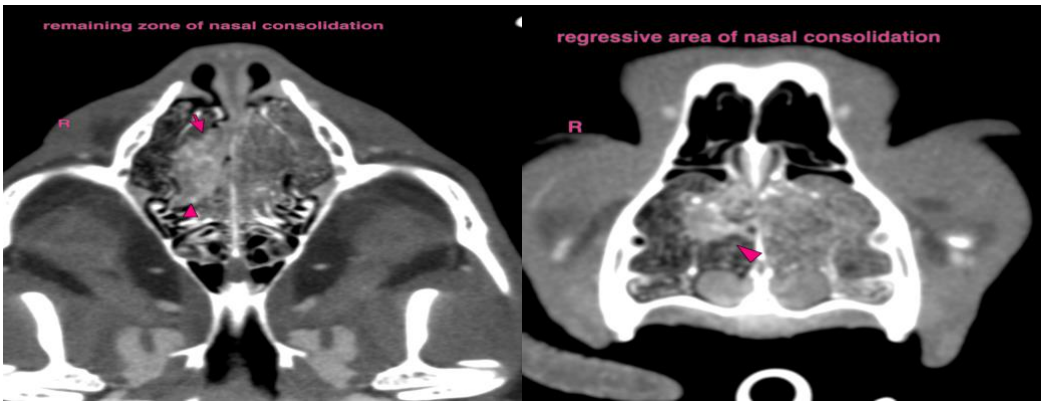

The information and recommendations provided are based on the images presented by the referring veterinarian/sonographer. No evaluation can be communicated regarding pathology that was not

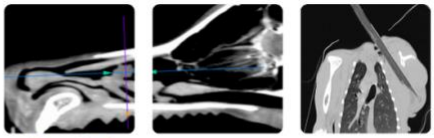

PATIENT

Doris Madden

SPECIES

Feline

BREED

DLH

SEX

Neutered Male

AGE

10 Years

WEIGHT

5.96 kg

INTERPRETED BY

Sebastian Schaub, DVM
Dr. med. vet. DipECVDI

IMAGING PERFORMED BY

BN

HOSPITAL NAME

Bridgwater Veterinary Hospital and Wellness Centre

REFERRING VET

Dr. Najot Brar

INVOICE

16307

DATE

05/15/26

visible in the image/video clips provided.

Thank you for this referral. If the clinical or image interpretation does not parallel your findings or if I can be of any further assistance please contact me.

Sebastian Schaub, DVM, Dr. med. vet. DipECVDI
info@sonopath.com