



PATIENT PRESENTING CLINICAL SIGNS

Kitty Benner History: Frank blood in stool off/on for several weeks. No change in response to antibiotics/probiotics.

SPECIES Abnormal PE/Chem/CBC/UA Results: Lab work all normal. No parasites on two separate fecal tests.

Canine COMPUTED TOMOGRAPHIC STUDY OF THE ABDOMEN

A high resolution pre- and post-contrast CT study of the abdomen is provided for review.

BREED COMPUTED TOMOGRAPHIC FINDINGS

Shih Tzu The serosal fat presents normal attenuation behavior. There is no evidence of peritoneal effusion or peritonitis.

SEX

Neutered Male Both kidneys present within normal limits for size, shape and organ architecture. After contrast administration a bilaterally symmetric and uniform nephro- and pyelogram is noted.

AGE

6 Years The adrenal glands are within normal limits for size, shape and organ architecture. Both liver and spleen present with normal shape, even surface, uniformly attenuating parenchyma and homogeneous contrast enhancement, unremarkable.

INTERPRETED BY

The portal vein presents a normal order of its tributary veins and intrahepatic branching. No abnormal vessel is noted inside and outside of the liver parenchyma.

Sebastian Schaub,
DVM Dr. med. vet.
DipECVDI

The pancreas is evenly contoured, the pancreatic parenchyma is homogeneous and presents uniform contrast enhancement.

HOSPITAL NAME

The position, delineation, wall and content of the gastrointestinal tract are considered within normal limits throughout.

Animal Health Care
Denver

The bony and surrounding soft tissue structures reveal no abnormalities.

COMPUTED TOMOGRAPHIC DIAGNOSIS

REFERRING VET

Cathryn Sayer

- Structural normal abdomen

INTERPRETATION OF THE FINDINGS & FURTHER RECOMMENDATIONS

INVOICE

15752

The CT study of the abdomen presents without abnormalities, explaining the blood in stool. No alterations of the colonic wall are appreciated. To rule out any intraluminal mural lesion of the colonic wall entirely – such as small polypoid lesion – workup might be complemented by colonoscopy. A CT

DATE

5/15/22



PATIENT

Kitty Benner

coloscopy by inflating the colon by gas might be considered alternatively, to eliminate folds/wrinkles that might hide smaller polyps – preceding enema would be beneficial to empty the colon as far as possible.

SPECIES

Canine

BREED

Shih Tzu

SEX

Neutered Male

AGE

6 Years

INTERPRETED BY

Sebastian Schaub,
DVM Dr. med. vet.
DipECVDI

HOSPITAL NAME

Animal Health Care
Denver

REFERRING VET

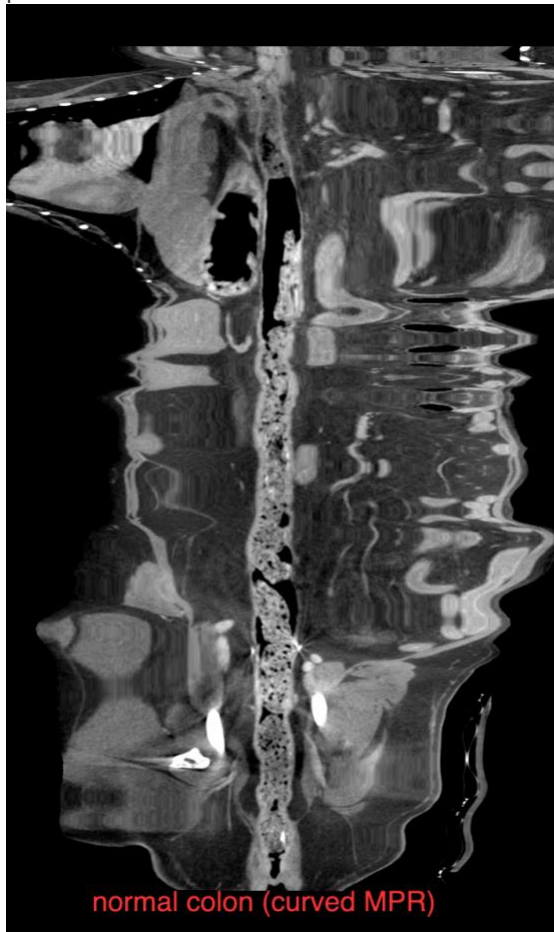
Cathryn Sayer

INVOICE

15752

DATE

5/15/22



The information and recommendations provided are based on the images presented by the referring veterinarian/sonographer. No evaluation can be communicated regarding pathology that was not visible in the image/video clips provided.

Thank you for this referral. If the clinical or image interpretation does not parallel your findings or if I can be of any further assistance please contact me.

Sebastian Schaub, Sebastian Schaub, DVM, Dr. med. vet. DipECVDI
sebast.schaub@gmail.com



PATIENT

Kitty Benner

SPECIES

Canine

BREED

Shih Tzu

SEX

Neutered Male

AGE

6 Years

INTERPRETED BY

Sebastian Schaub,
DVM Dr. med. vet.
DipECVDI

HOSPITAL NAME

Animal Health Care
Denver

REFERRING VET

Cathryn Sayer

INVOICE

15752

DATE

5/15/22