



PATIENT

Hank Klopfenstein

SPECIES

Rabbit

BREED

Holland Lop

SEX

MN

AGE

3

WEIGHT

2.48kg

INTERPRETED BY

Sebastian Schaub, DVM
Dr. med. vet.
DipECVDI

IMAGING PERFORMED BY

RJ

HOSPITAL NAME

Emergency Veterinary
Hospital of Ann Arbor

REFERRING VET

Dr. Ivana Levy

INVOICE

74997

DATE

5-14-26

PRESENTING CLINICAL SIGNS

email submission for stat read. HX of liver lobe torsion in december 2025 that was managed medically. presenting for signs of GI stasis 12-18 hour duration. Suspect liver lobe torsion & possible GDV, Abnormal PE/Chem/CBC/UA Results: ALT 1857, hypoglycemia: 136, CBC WNL

RADIOGRAPHIC STUDY OF THE ABDOMEN

Radiographs of the abdomen in two orthogonal image planes are provided for review.

RADIOGRAPHIC FINDINGS

The surrounding bony structures are within normal limits.

In the subcutaneous tissue at the caudodorsal aspect of the thoracic spine, multiple small gas bubbles are visible.

The serosal detail is maintained throughout the peritoneal and retroperitoneal space.

The stomach is distended by foamy material. In the lateral view, the stomach has an atypical C-shaped conformation. In the VD view the large fundic part of the stomach is located in the right cranial abdominal quadrant and the pyloric region is positioned in the left cranial abdominal quadrant.

The small intestinal loops are segmentally mildly distended by gas and foamy chymus.

RADIOGRAPHIC DIAGNOSIS

- Malposition of stomach

INTERPRETATION OF THE FINDINGS & FURTHER RECOMMENDATIONS

The radiographic study is supporting the diagnosis of gastric dilation and volvulus – surgical management is indicated.

Liver lobe torsion cannot be diagnosed on radiographs alone.



PATIENT

Hank Klopfenstein

SPECIES

Rabbit

BREED

Holland Lop

SEX

MN

AGE

3

WEIGHT

2.48kg

INTERPRETED BY

Sebastian Schaub, DVM
Dr. med. vet.
DipECVDI

IMAGING PERFORMED BY

RJ

HOSPITAL NAME

Emergency Veterinary
Hospital of Ann Arbor

REFERRING VET

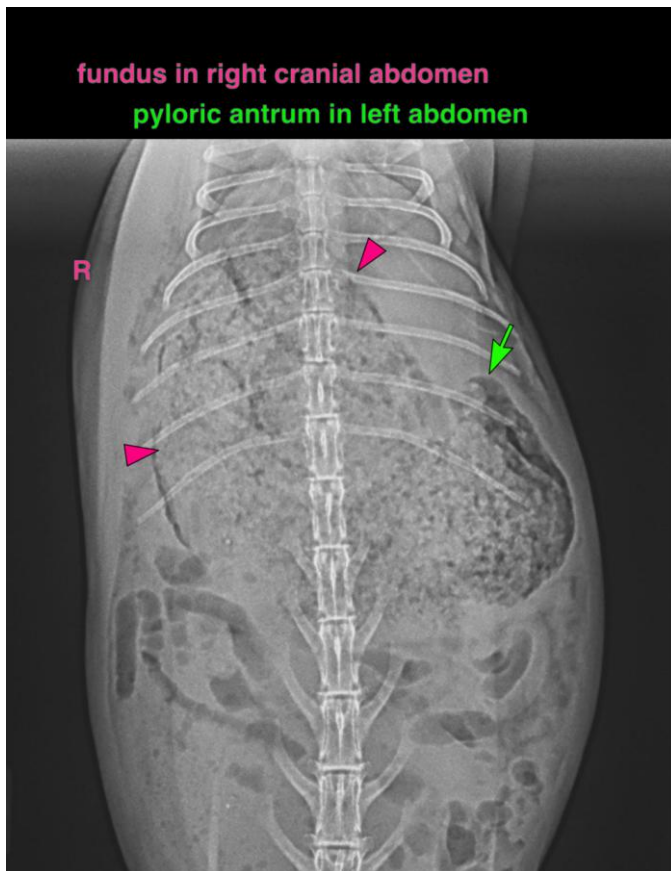
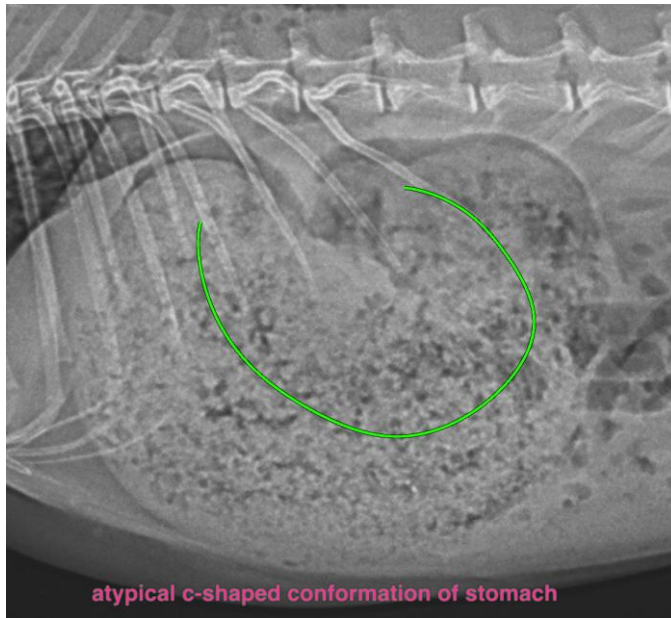Dr. Ivana Levy

INVOICE

74997

DATE

5-14-26





PATIENT

Hank Klopfenstein

SPECIES

Rabbit

BREED

Holland Lop

SEX

MN

AGE

3

WEIGHT

2.48kg

INTERPRETED BY

Sebastian Schaub, DVM
Dr. med. vet.
DipECVDI

IMAGING PERFORMED BY

RJ

HOSPITAL NAME

Emergency Veterinary
Hospital of Ann Arbor

REFERRING VET

Dr. Ivana Levy

INVOICE

74997

DATE

5-14-26

The information and recommendations provided are based on the images presented by the referring veterinarian/sonographer. No evaluation can be communicated regarding pathology that was not visible in the image/video clips provided.

Thank you for this referral. If the clinical or image interpretation does not parallel your findings or if I can be of any further assistance please contact me.

Sebastian Schaub, Sebastian Schaub, DVM, Dr. med. vet. DipECVDI
info@sonopath.com