



PATIENT

Charlie Riege

SPECIES

Canine

BREED

Labrador Retriever

SEX

Male N

AGE

11Y

WEIGHT

75lbs

INTERPRETED BY

Sebastian Schaub, DVM
Dr. med. vet.
DipECVDI

IMAGING PERFORMED BY

Monika Salgado

HOSPITAL NAME

Westchester Animal
Hospital

REFERRING VET

Randy Dominguez

INVOICE

75010

DATE

5-14-26

PRESENTING CLINICAL SIGNS

Referred from My Pet Hospital. Presented with a bilateral osteoarthritis with concomitant flexor and extensor enthesopathy. CT for elbow dysplasia.

Abnormal PE/Chem/CBC/UA Results: Unremarkable.

COMPUTED TOMOGRAPHY OF THE ELBOW JOINTS

A high resolution pre- and post-contrast CT study of the elbow joints is provided for review.

COMPUTED TOMOGRAPHIC FINDINGS

The periarticular bones of both elbow joints present advanced osteophyte new bone formation. The medial coronoid process of both elbow joints is irregular and has a heterogeneous density. Along the joint capsule of both elbow joints, multiple well-defined, variable sized, mineralization are seen. The subchondral bone of the right trochlea humeri presents a mild irregular surface.

The proximal aspect of the flexor muscles of the right elbow joint present multiple irregular mineralization.

COMPUTED TOMOGRAPHIC DIAGNOSIS

- Coronoid disease elbow joint bilaterally
- Advances osteoarthritis elbow joint bilaterally
- Contact lesion right trochlea humeri
- Metaplasia along the joint capsule both elbow joints
- Right sided flexor enthesiopathy with metaplasia

INTERPRETATION OF THE FINDINGS & FURTHER RECOMMENDATIONS

The CT findings are fitting the history of advanced degenerative joint disease of both elbow joints due to elbow dysplasia. The contact lesion of the right trochlea humeri is indicative for loss of joint cartilage. The appreciated changes are irreversible, and conservative management may be the preferred management option here.



PATIENT

Charlie Riege

SPECIES

Canine

BREED

Labrador Retriever

SEX

Male N

AGE

11Y

WEIGHT

75lbs

INTERPRETED BY

Sebastian Schaub, DVM
Dr. med. vet.
DipECVDI

IMAGING PERFORMED BY

Monika Salgado

HOSPITAL NAME

Westchester Animal
Hospital

REFERRING VET

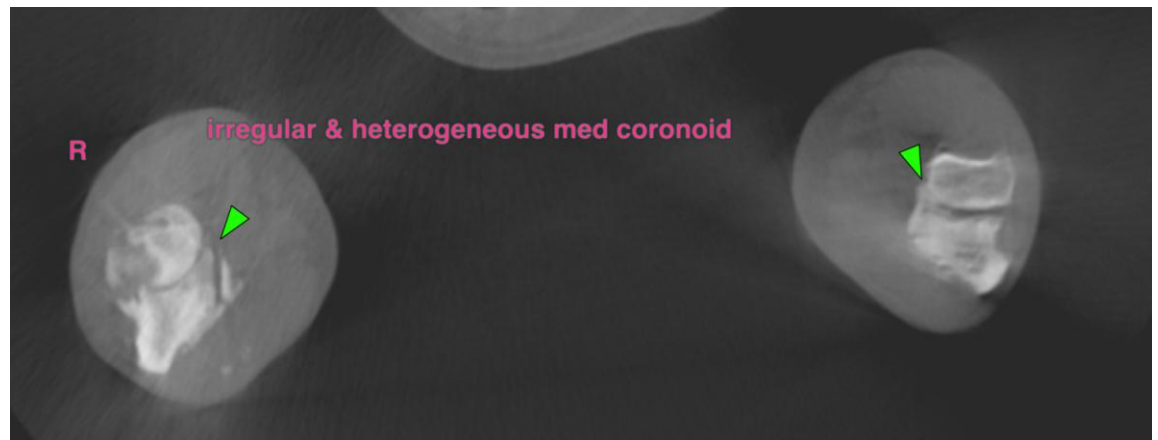
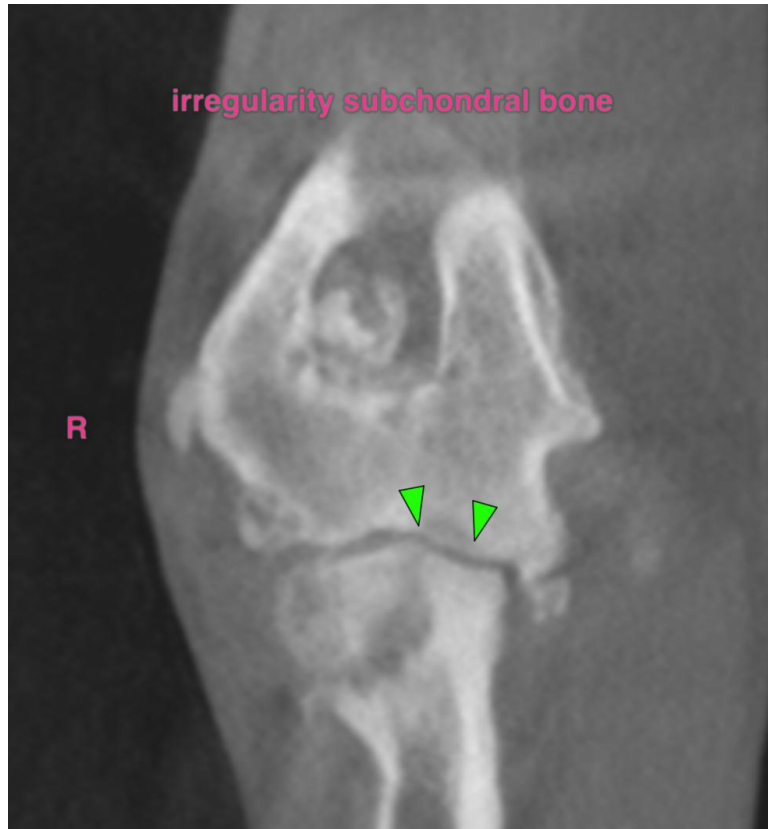Randy Dominguez

INVOICE

75010

DATE

5-14-26





PATIENT

Charlie Riege

SPECIES

Canine

BREED

Labrador Retriever

SEX

Male N

AGE

11Y

WEIGHT

75lbs

INTERPRETED BY

Sebastian Schaub, DVM
Dr. med. vet.
DipECVDI

IMAGING PERFORMED BY

Monika Salgado

HOSPITAL NAME

Westchester Animal
Hospital

REFERRING VET

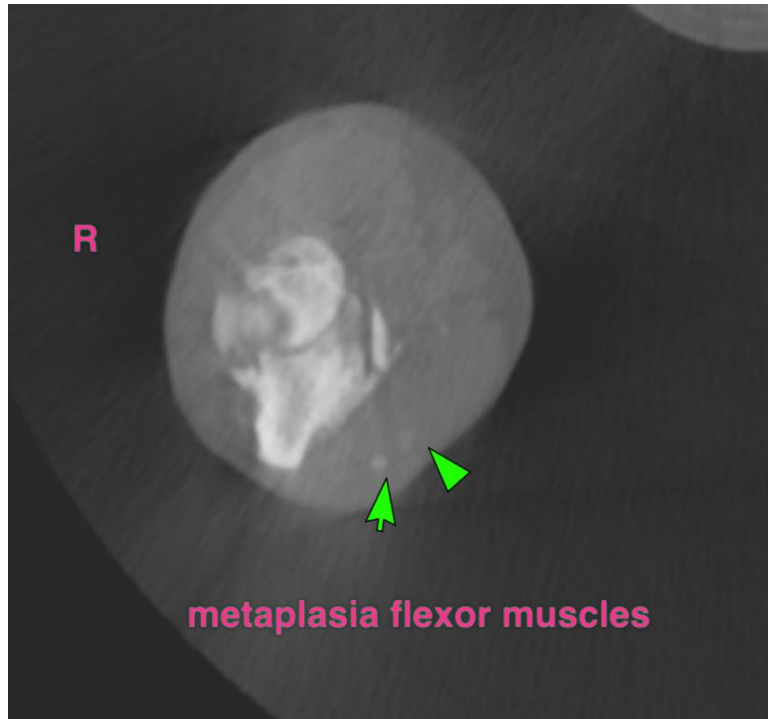
Randy Dominguez

INVOICE

75010

DATE

5-14-26



The information and recommendations provided are based on the images presented by the referring veterinarian/sonographer. No evaluation can be communicated regarding pathology that was not visible in the image/video clips provided.

Thank you for this referral. If the clinical or image interpretation does not parallel your findings or if I can be of any further assistance please contact me.

Sebastian Schaub, Sebastian Schaub, DVM, Dr. med. vet. DipECVDI
info@sonopath.com