



PATIENT PRESENTING CLINICAL SIGNS

Nani Lewis P has a chronic history of cough and concerning respiratory pattern. P is overweight/obese. Collapsing trachea has been diagnosed via radiograph imaging in the past. O notes that she has become more concerned about P's anxiety, increased respiratory difficulty in times of excitement and stress, and notes that P appears to have "pauses" in respiration while in deep sleep. No respiratory distress is noted. P has is taking Butorphanol tablets intermittently and had previously been on hydrocodone, but O was unhappy with sedative effects
SPECIES Canine
BREED Yorkie Mix
SEX Female Spayed
AGE 15 Years

Abnormal PE/Chem/CBC/UA Results: BW from 02/22 - ALT 120/118 - Increased PLTs and TRIG - LYM 31/30

RADIOGRAPHIC STUDY OF THE THORAX

Radiographs of the thorax in three imaging planes are provided for review.

RADIOGRAPHIC FINDINGS

The body condition score is 8/9.

The costal cartilages present moderate degenerative changes. The periarticular bones of both elbow joints present moderate osteophyte new bone formation.

Multiple cutaneous nodules are seen dorsal to the thoracic spine.

The heart is of normal size and shape, there is no evidence of cardiac chamber or vascular enlargement. The pulmonary vasculature is within normal limits.

The mediastinum is moderately widened by fat.

Mild to moderate dynamic dorsoventral flattening of the caudal intrathoracic tracheal segment is seen.

The bronchial tree presents with thin walls and tapers uniformly towards the periphery as expected.

The diaphragm is bulging far cranially in the lateral view and the pulmonary volume is generalized decreased, accentuating an unstructured reticular lung pattern – far less pronounced in the VD view of the thorax.

In the imaging plane of the renal pelvis bilaterally, large mineralization are appreciated.

RADIOGRAPHIC DIAGNOSIS

- Obesity
- Suspect mild tracheal collapse intrathoracic segment
- Generalized mild to moderate unstructured interstitial lung pattern
- Degenerative osteoarthritis elbow joints bilaterally
- Multiple non-specific (sub)cutaneous nodules dorsal to thoracic spine
- Degenerative changes costal cartilages
- Nephrolithiasis

INVOICE

52184

DATE

5-13-22

INTERPRETED BY

Sebastian Schaub, DVM
 Dr. med. vet. DipECVDI

HOSPITAL NAME

Boca Park Animal
 Hospital

REFERRING VET

Tifanie Silver



PATIENT

Nani Lewis

SPECIES

Canine

BREED

Yorkie Mix

SEX

Female Spayed

AGE

15 Years

INTERPRETED BY

Sebastian Schaub, DVM
Dr. med. vet. DipECVDI

HOSPITAL NAME

Boca Park Animal
Hospital

REFERRING VET

Tifanie Silver

INVOICE

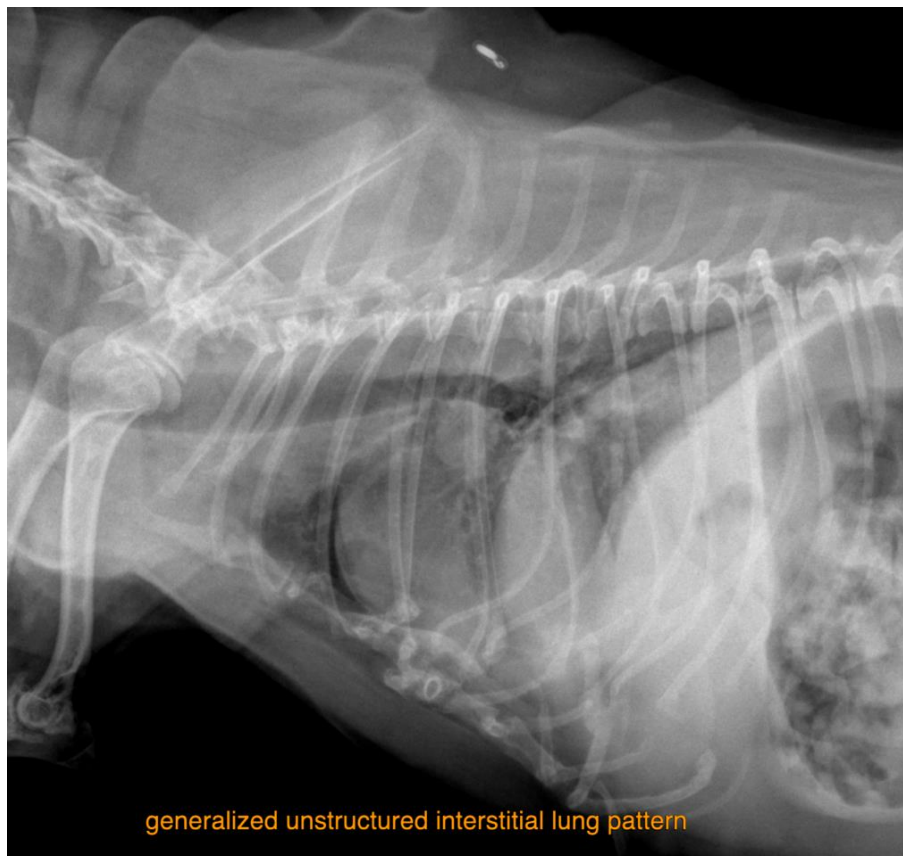
52184

DATE

5-13-22

INTERPRETATION OF THE FINDINGS & FURTHER RECOMMENDATIONS

The unstructured interstitial lung pattern is likely a sequela to the nutritional status, hypoinflation of the lung and age related changes of the lung parenchyma. Differentials for an unstructured interstitial pattern are not specific and would include fibrosis, pneumonitis (inflammatory versus infectious), systemic disease (e.g. pancreatitis, IMHA, renal disease), neoplasia. Overall, the odds for inflammatory non-infectious lower airway disease appear high (e.g. eosinophilic, neutrophilic, mixed) and clinical signs might be exacerbated by the mild tracheal collapse. Obesity is also a known predisposing factor for cough and weight management appears beneficial.





PATIENT

Nani Lewis

The information and recommendations provided are based on the images presented by the referring veterinarian/sonographer. No evaluation can be communicated regarding pathology that was not visible in the image/video clips provided.

Thank you for this referral. If the clinical or image interpretation does not parallel your findings or if I can be of any further assistance please contact me.

SPECIES

Canine

Sebastian Schaub, Sebastian Schaub, DVM, Dr. med. vet. DipECVDI
sebast.schaub@gmail.com

BREED

Yorkie Mix

SEX

Female Spayed

AGE

15 Years

INTERPRETED BY

Sebastian Schaub, DVM
Dr. med. vet. DipECVDI

HOSPITAL NAME

Boca Park Animal
Hospital

REFERRING VET

Tifanie Silver

INVOICE

52184

DATE

5-13-22