



## PATIENT

Penny Martino

## SPECIES

Canine

## BREED

King Charles

## SEX

Spayed Female

## AGE

10 Years

## WEIGHT

17.5 lbs

## INTERPRETED BY

Sebastian Schaub, DVM  
Dr. med. vet. DipECVDI

## IMAGING PERFORMED BY

Dr. Mucera

## HOSPITAL NAME

Animal Clinic of  
Queens

## REFERRING VET

Dr. Mucera

## INVOICE

16138

## DATE

05/11/26

## PRESENTING CLINICAL SIGNS

Pt has 3/6 HM. Had an echo on the 5/7/26 (Degenerative mitral and tricuspid valve disease. Mild pulmonary hypertension. Elevated left atrial pressures.)

## RADIOGRAPHIC STUDY OF THE THORAX

Radiographs of the thorax in three imaging planes are provided for review.

## RADIOGRAPHIC FINDINGS

The surrounding bony structures are within normal limits.

The extrathoracic soft tissues present homogeneous without abnormalities.

The caudal contour of the cardiac silhouette is steep and the caudal cardiac waist is lost. The vertebral heart score is The pulmonary vasculature is within normal limits.

The cranial mediastinum presents the expected soft tissue opacity. The mediastinal width is less than twice the width of the vertebral column at the same level.

The trachea is normal in diameter and presents the anticipated course. The luminal outline of the trachea is smooth.

The bronchial tree presents with thin walls and tapers uniformly towards the periphery as expected.

The lung parenchyma presents the expected architecture and opacity; the intrapulmonary vascular branching is seen up to the third order lung vessels.

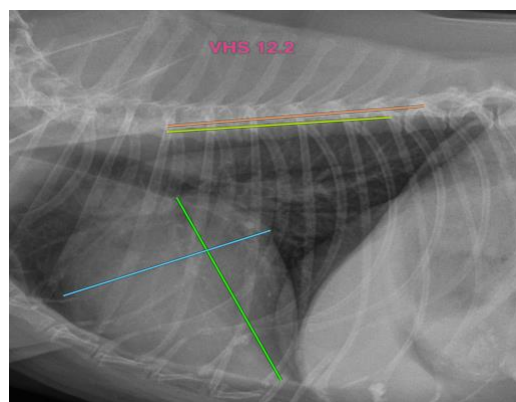
The diaphragm is well delineated with even surface and the expected mild cranial bulging of the diaphragmatic cupola.

## RADIOGRAPHIC DIAGNOSIS

- Mild cardiomegaly without signs of decompensation

## INTERPRETATION OF THE FINDINGS & FURTHER RECOMMENDATIONS

The generalized mild cardiomegaly is fitting the history of mitral valve disease. No abnormalities of the lower airways are appreciated nor are there signs of decompensation.



The information and recommendations provided are based on the images presented by the referring



## PATIENT

Penny Martino

## SPECIES

Canine

## BREED

King Charles

## SEX

Spayed Female

## AGE

10 Years

## WEIGHT

17.5 lbs

## INTERPRETED BY

Sebastian Schaub, DVM  
Dr. med. vet. DipECVDI

## IMAGING PERFORMED BY

Dr. Mucera

## HOSPITAL NAME

Animal Clinic of  
Queens

## REFERRING VET

Dr. Mucera

## INVOICE

16138

## DATE

05/11/26

veterinarian/sonographer. No evaluation can be communicated regarding pathology that was not visible in the image/video clips provided.

Thank you for this referral. If the clinical or image interpretation does not parallel your findings or if I can be of any further assistance please contact me.

**Sebastian Schaub, DVM, Dr. med. vet. DipECVDI**  
[info@sonopath.com](mailto:info@sonopath.com)