



PATIENT

Coco Delogu

PRESENTING CLINICAL SIGNS

PU/PD
Abnormal PE/Chem/CBC/UA Results: unremarkable

SPECIES

Canine

RADIOGRAPHIC STUDY OF THE ABDOMEN

Radiographs of the abdomen in three imaging planes are provided for review.

BREED

Soft Coated Wheaten
Terrier

RADIOGRAPHIC FINDINGS

The intervertebral disc space L4/L5 is mildly narrowed.

No abnormalities of the extraabdominal soft tissues are noted. The abdominal wall is smooth and thin.

The serosal detail is maintained throughout the peritoneal and retroperitoneal space.

SEX

Female Spayed

The hepatic volume is moderately increased the liver is protruding beyond the costal arch; the gastric axis is deviated caudally. The caudoventral hepatic margins are rounded.

The splenic head is in the anticipated position and within normal limits for size and opacity. The splenic body and tail are considered normal for position, size, shape and opacity.

AGE

9 Years

Both kidneys are seen and present with normal size, shape, delineation and opacity. The urinary bladder is in its anticipated position. No radiopaque calculi are noted throughout the upper and lower urinary tract.

INTERPRETED BY

Sebastian Schaub, DVM
Dr. med. vet. DipECVCI

The stomach is in its anticipated position and presents normal content.

The small intestinal loops are of even diameter and non-dilated, a small amount of gas is seen within the small intestinal loops and considered within normal limits.

The colon is seen in the expected position and presents with appropriate content.

HOSPITAL NAME

St. Catherine's Animal
Hospital

RADIOGRAPHIC DIAGNOSIS

- Hepatomegaly
- Suspect discopathy L4/L5

REFERRING VET

Dr. Boctor

INTERPRETATION OF THE FINDINGS & FURTHER RECOMMENDATIONS

Potentials for the hepatomegaly include metabolic hepatic disease/steroid induced hepatopathy, hepatitis or neoplastic infiltration. Ultrasound including FNA sampling can be used as minimally advanced diagnostic tests.

INVOICE

52557

No additional abnormalities are appreciated as potential source for the presenting clinical signs.

DATE

5-11-22



PATIENT

Coco Delogu

SPECIES

Canine

BREED

Soft Coated Wheaten
Terrier

SEX

Female Spayed

AGE

9 Years

INTERPRETED BY

Sebastian Schaub, DVM
Dr. med. vet. DipECVDI

HOSPITAL NAME

St. Catherine's Animal
Hospital

REFERRING VET

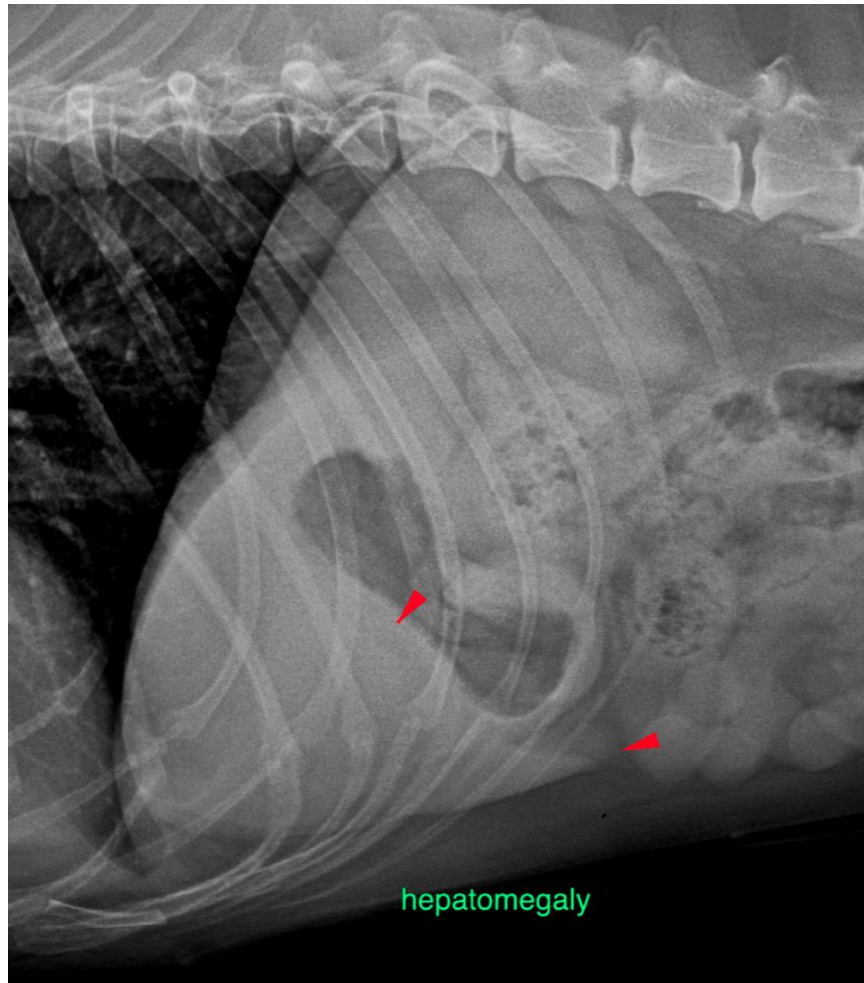
Dr. Boctor

INVOICE

52557

DATE

5-11-22



The information and recommendations provided are based on the images presented by the referring veterinarian/sonographer. No evaluation can be communicated regarding pathology that was not visible in the image/video clips provided.

Thank you for this referral. If the clinical or image interpretation does not parallel your findings or if I can be of any further assistance please contact me.

Sebastian Schaub, Sebastian Schaub, DVM, Dr. med. vet. DipECVDI
sebast.schaub@gmail.com