



PATIENT PRESENTING CLINICAL SIGNS

Waffles Cat Republic
Rescue HX ear infections

COMPUTED TOMOGRAPHY OF THE SKULL & THORAX

A high resolution post-contrast CT study of the skull and thorax are provided for review.

SPECIES

Feline

COMPUTED TOMOGRAPHIC FINDINGS

Skull

Multiple teeth are absent.

BREED

DSH

The nasal cavity presents the expected aerated spaces between thin & even conchae and turbinates with smooth mucosal lining.

Both ocular bulbs are absent.

SEX

MN

Both temporomandibular joints present congruent joint spaces with even subchondral bone surfaces and are considered within normal limits.

AGE

7 Years

Both tympanic bullae are aerated, the mucosal lining is not seen, the bony wall is smooth and thin. The horizontal segment of the right external ear canal is occupied by an expansile, heterogeneous contrast enhancing mass that is confined to the right external ear canal. The left external ear canal presents a thickened, serrating epithelial lining.

INTERPRETED BY

Sebastian Schaub, DVM
Dr. med. vet. DipECVDI

The brain presents no deviation from normal anatomy and symmetry. The brain parenchyma is homogeneous and within normal limits for attenuation and distribution of contrast enhancement. The ventricular system is non-dilated and symmetric.

The right lateral retropharyngeal lymph node is prominent.

Thorax

HOSPITAL NAME

Animal Surgical
Center

Multiple sternebra are fused. Spondylosis formation is seen along the thoracolumbar junction.

The sternal, cranial mediastinal and tracheobronchial lymph nodes are small elongated with a normal short-to-long-axis-ratio is < 0.5, the attenuation and contrast enhancement pattern is uniform and considered within normal limits.

REFERRING VET

Rescue

The cardiovascular structures including the pulmonary vasculature are within normal limits.

The bronchial tree presents with regular branching and tapers uniformly towards the periphery as expected, the bronchial walls are thin and smooth. The bronchus-to-artery ratio is within normal limits.

INVOICE

58247

The volume of the lung lobes is decreased – accentuated in the cranioventral aspects of the lung – and the pulmonary parenchyma is consolidated with air-bronchograms. The lung parenchyma presents the expected architecture and attenuation behavior.

Small incidental gas pockets are seen within the esophageal lumen, there is no evidence of abnormal dilation.

DATE

5-10-23



PATIENT COMPUTED TOMOGRAPHIC DIAGNOSIS

Waffles Cat Republic
Rescue

- Intraluminal soft tissue mass right external ear canal
- Left sided otitis externa
- Lymphadenopathy lateral retropharyngeal lymph node
- History of bilateral ocular enucleation
- Multiple absent teeth
- No evidence

SPECIES

Feline

INTERPRETATION OF THE FINDINGS & FURTHER RECOMMENDATIONS

BREED

DSH

The soft tissue mass in the right external ear canal is highly suggestive for primary neoplasia, such as squamous cell carcinoma or ceruminous gland carcinoma. Biopsy can be performed to confirm the diagnosis. Right sided total ear canal ablation is considered as the therapy of choice.

Recommend FNA sampling of the right lateral retropharyngeal lymph node to rule out metastatic disease.

SEX

MN

The thoracic CT study is negative for metastatic disease, however smaller parenchymal pulmonary lesions can be effaced in the consolidated areas of the lung parenchyma.

AGE

7 Years

INTERPRETED BY

Sebastian Schaub, DVM
Dr. med. vet. DipECVDI

HOSPITAL NAME

Animal Surgical
Center

REFERRING VET

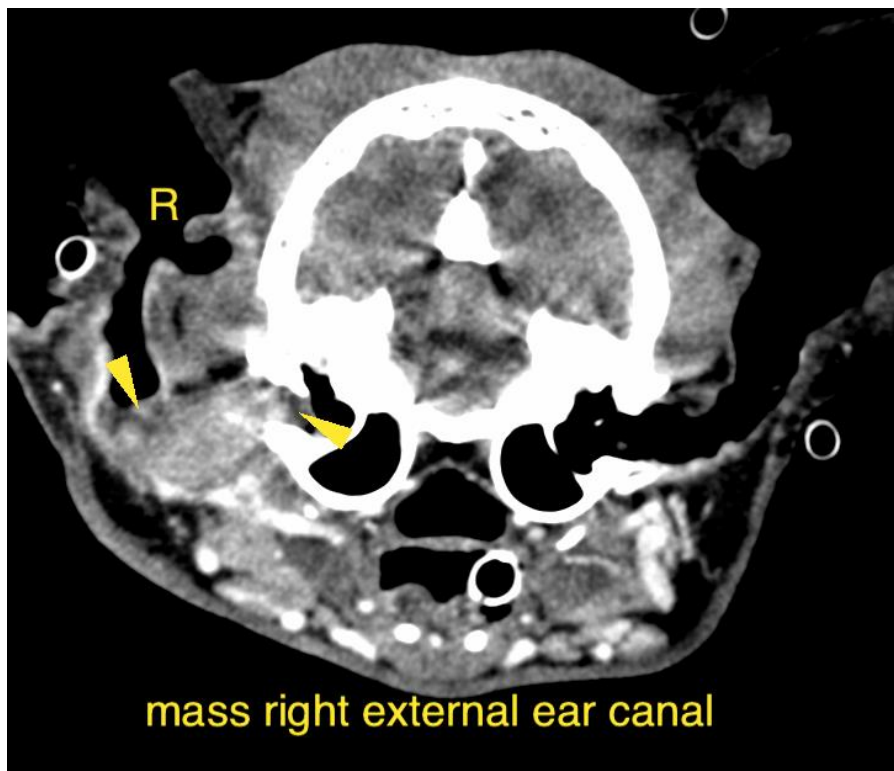
Rescue

INVOICE

58247

DATE

5-10-23





PATIENT

Waffles Cat Republic
Rescue

SPECIES

Feline

BREED

DSH

SEX

MN

AGE

7 Years

INTERPRETED BY

Sebastian Schaub, DVM
Dr. med. vet. DipECVDI

HOSPITAL NAME

Animal Surgical
Center

REFERRING VET

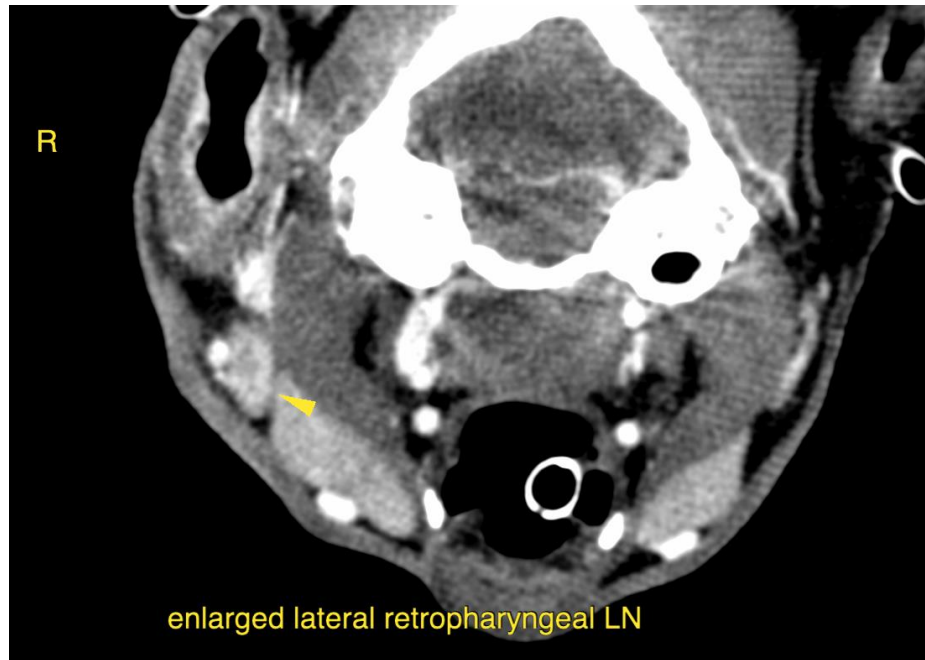
Rescue

INVOICE

58247

DATE

5-10-23



The information and recommendations provided are based on the images presented by the referring veterinarian/sonographer. No evaluation can be communicated regarding pathology that was not visible in the image/video clips provided.

Thank you for this referral. If the clinical or image interpretation does not parallel your findings or if I can be of any further assistance please contact me.

Sebastian Schaub, Sebastian Schaub, DVM, Dr. med. vet. DipECVDI
sebast.schaub@gmail.com