



PATIENT PRESENTING CLINICAL SIGNS

Daisy Muller Last 3-4 months limping Discussed at wellness in March Will toe touch off and on Has trouble getting up the stairs Not worse but not better Will use only LH to get in the car Will not even attempt to jump in the truck Did not feed this morning just in case

SPECIES Abnormal PE/Chem/CBC/UA Results: Ambulatory X 4, LAME ON RIGHT HIND MEDIAL BUTTRESS AND PAIN WITH MANIPULATION OF RIGHT HIND No loss of proprioception. 3/30/23-Senior Panel done-WNL
Canine

RADIOGRAPHIC STUDY OF THE PELVIS AND STIFLE JOINTS

BREED A complete set of radiographs of the pelvis and the stifle joints is provided for review.

Border Collie **RADIOGRAPHIC FINDINGS**

SEX The osseous and surrounding soft tissue structures of the pelvis are within normal limits. Both coxofemoral joints present smooth osseous margins and congruent joint spaces.

Spayed The volume of the soft tissue shadow of the right thigh musculature is moderately decreased.

AGE The periarticular bones of the right stifle joint present moderate osteophyte new bone formation and a significant intracapsular soft tissue swelling of the right stifle joint is appreciated – compressing the infrapatellar fat-pad cranially and the fascial plane caudally.

3 Years, 1 Month The left stifle joint presents smooth osseous margins and without signs of intracapsular soft tissue swelling.

INTERPRETED BY RADIOGRAPHIC DIAGNOSIS

Sebastian Schaub, DVM
Dr. med. vet. DipECVDI

- Degenerative osteoarthritis right stifle joint
- Articular swelling right stifle joint
- Disuse atrophy right thigh musculature
- Normal pelvis & coxofemoral joints
- Normal left stifle joint

HOSPITAL NAME

Elizabeth Animal Hospital

INTERPRETATION OF THE FINDINGS & FURTHER RECOMMENDATIONS

REFERRING VET

Kim Allyn, DVM

The radiographic study is consistent with chronic degenerative osteoarthritis with concomitant joint effusion of the right stifle joint. The most-likely underlying cause is (partial) rupture of the cranial cruciate ligament with or without meniscal disease.

A positive drawer sign or tibial compression test under general anesthesia can be used to confirm the diagnosis.

INVOICE

58226

DATE

5-10-23



PATIENT

Daisy Muller

SPECIES

Canine

BREED

Border Collie

SEX

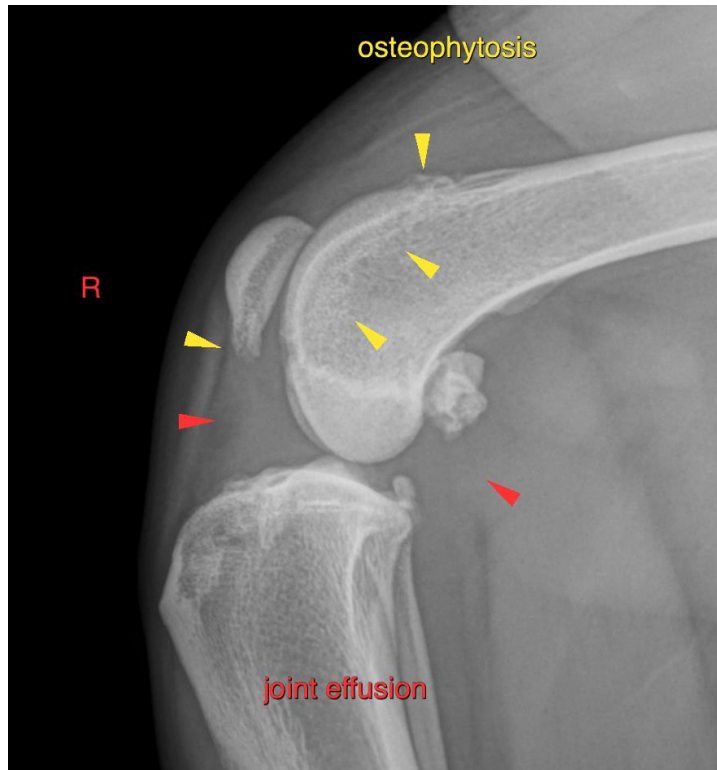
Spayed

AGE

3 Years, 1 Month

INTERPRETED BY

Sebastian Schaub, DVM
Dr. med. vet. DipECVDI



HOSPITAL NAME

Elizabeth Animal
Hospital

REFERRING VET

Kim Allyn, DVM

INVOICE

58226

DATE

5-10-23

The information and recommendations provided are based on the images presented by the referring veterinarian/sonographer. No evaluation can be communicated regarding pathology that was not visible in the image/video clips provided.

Thank you for this referral. If the clinical or image interpretation does not parallel your findings or if I can be of any further assistance please contact me.

Sebastian Schaub, Sebastian Schaub, DVM, Dr. med. vet. DipECVDI
sebast.schaub@gmail.com