



PATIENT PRESENTING CLINICAL SIGNS

Arya Buhot hx of asthma, and getting oral steroids, and now transitioned to inhalant steroids.
Abnormal PE/Chem/CBC/UA Results: normal

SPECIES RADIOGRAPHIC STUDY OF THE THORAX

Feline Radiographs of the thorax in three imaging planes are provided for review.

RADIOGRAPHIC FINDINGS

BREED The surrounding bony structures are within normal limits.

Siames Mix The extrathoracic soft tissues present homogeneous without abnormalities.

The heart is of normal size and shape, there is no evidence of cardiac chamber or vascular enlargement. The pulmonary vasculature is within normal limits.

SEX An endotracheal tube is appreciated in the cervical segment of the trachea. The trachea is normal in diameter and presents the anticipated course. The luminal outline of the trachea is smooth.

FS

Generalized moderate peribronchial cuffing is appreciated.

AGE The lung parenchyma presents a generalized ground glass opacification and has a decreased volume – considered secondary to general anesthesia and hypoinflation of the lung parenchyma.

7 Years

The diaphragm is well delineated with even surface and the expected mild cranial bulging of the diaphragmatic cupola.

INTERPRETED BY

RADIOGRAPHIC DIAGNOSIS

Sebastian Schaub, DVM
Dr. med. vet. DipECVDI

- Moderate bronchial lung pattern without signs of air-trapping

HOSPITAL NAME INTERPRETATION OF THE FINDINGS & FURTHER RECOMMENDATIONS

Balmy Beach Pet Hospital The bronchial lung pattern is fitting the history of feline bronchial disease ('feline asthma') – commonly primary allergic in origin. No additional abnormalities are appreciated.

REFERRING VET

Dr. Singh

INVOICE

58230

DATE

5-10-23



PATIENT

Arya Buhot

SPECIES

Feline

BREED

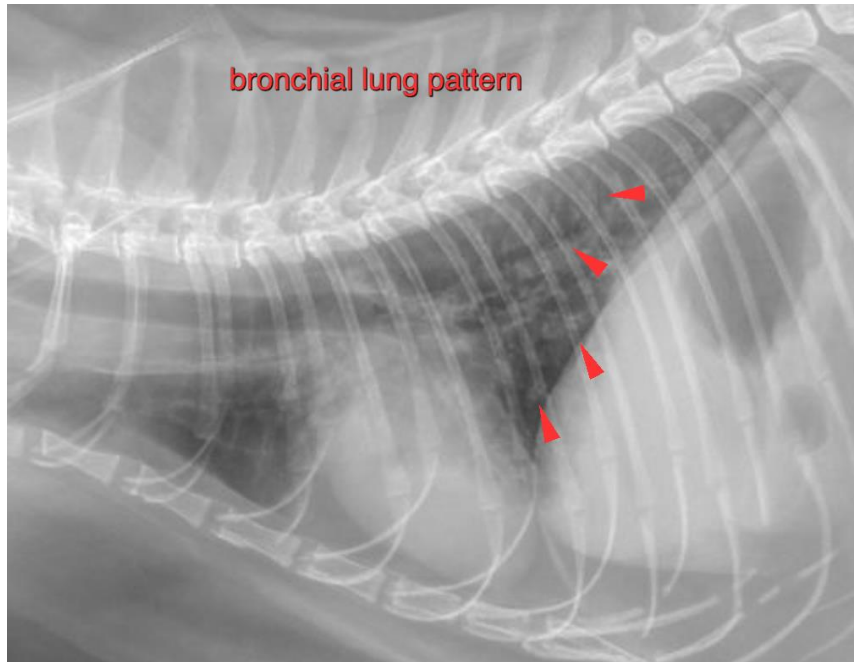
Siames Mix

SEX

FS

AGE

7 Years



INTERPRETED BY

Sebastian Schaub, DVM
Dr. med. vet. DipECVDI

The information and recommendations provided are based on the images presented by the referring veterinarian/sonographer. No evaluation can be communicated regarding pathology that was not visible in the image/video clips provided.

HOSPITAL NAME

Balmy Beach Pet
Hospital

Thank you for this referral. If the clinical or image interpretation does not parallel your findings or if I can be of any further assistance please contact me.

Sebastian Schaub, Sebastian Schaub, DVM, Dr. med. vet. DipECVDI
sebast.schaub@gmail.com

REFERRING VET

Dr. Singh

INVOICE

58230

DATE

5-10-23