



**PATIENT PRESENTING CLINICAL SIGNS**

Luna Santiago ACUTE ONSET OF TETRAPLEGIA WITH DECREASED DEEP PAIN AND

**COMPUTED TOMOGRAPHY OF THE CERVICAL SPINE**

**SPECIES** A plain and myelographic CT study of the cervical spine in a bone and soft tissue reconstruction is provided for review.

Canine

**COMPUTED TOMOGRAPHIC FINDINGS**

**BREED**

In the ventral aspect of the vertebral canal level with C2, mild undulating material is seen, distorting the ventral subarachnoid space at the same level.

Siberian Husky

Level with C3, in the left laterodorsal aspect of the vertebral canal, mild hyperattenuating (120HU) material is seen, occupying approximately 80% of the cross-sectional area of the vertebral canal at the same level. The mild hyperattenuating material is extending over the complete length of the left lamina of C3. The spinal cord at the same level is displaced to the right and ventrally and compressed.

**SEX**

F

The left proximal humerus presents a zone with moth eaten osteolytic lesions and immature periosteal new bone formation.

**AGE**

4

**COMPUTED TOMOGRAPHIC DIAGNOSIS**

- Extradural mild hyperattenuating material in the left laterodorsal aspect level with C3 with compressive myelopathy
- Extradural lesion ventral aspect of C2 without compressive myelopathy
- Monostotic aggressive osteoproliferative lesion left proximal humerus

**INTERPRETED BY**

Sebastian Schaub, DVM  
Dr. med. vet. DipECVDI

**INTERPRETATION OF THE FINDINGS & FURTHER RECOMMENDATIONS**

**HOSPITAL NAME**

In combination with the acute onset of clinical signs and the hyperattenuating pattern of the material in the vertebral canal level with C3, the odds for epidural hemorrhage with secondary spinal cord compression are high. There is an aggressive bone lesion of the left proximal humerus, increasing the odds for underlying neoplastic. Recommend full tumor staging and screening for primary neoplasia – such as hemangiosarcoma, round cell tumor.

JUANA DIAZ  
ANIMAL HOSPITAL

**REFERRING VET**

Rivera

Other potentials would include infectious disease (e.g. Angiostrongylus infection, Ehrlichiosis, mycotic infection), intoxication (e.g. Warfarin), systemic hypertension, congenital coagulopathy, hepatic disease.

**INVOICE**

52029

Based on the results of the advanced diagnostic tests, surgical decompression from a lateral approach level with C3 would be the therapy of choice.

**DATE**

5-10-22



**PATIENT**

Luna Santiago

**SPECIES**

Canine

**BREED**

Siberian Husky

**SEX**

F

**AGE**

4

**INTERPRETED BY**

Sebastian Schaub, DVM  
Dr. med. vet. DipECVDI

**HOSPITAL NAME**

JUANA DIAZ  
ANIMAL HOSPITAL

**REFERRING VET**

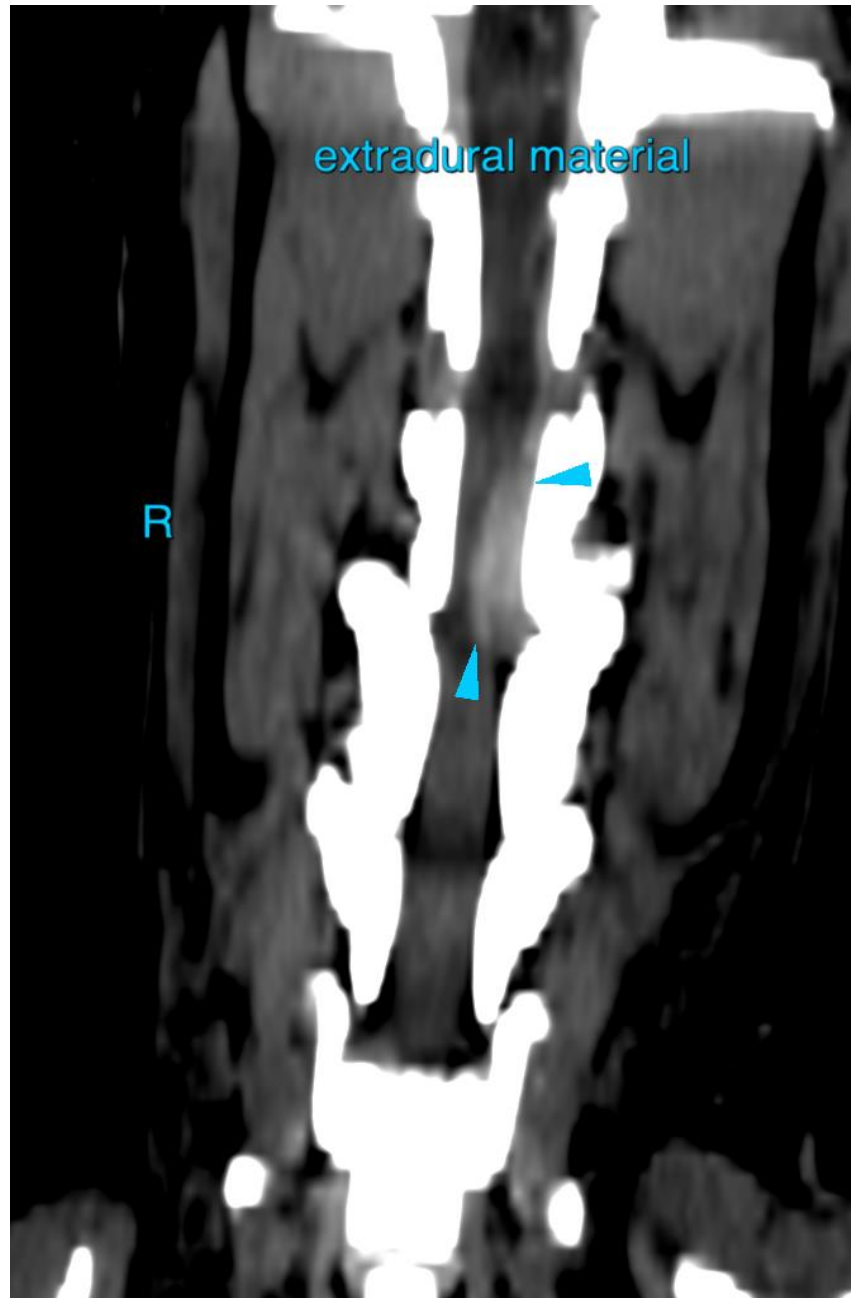
Rivera

**INVOICE**

52029

**DATE**

5-10-22





**PATIENT**

Luna Santiago

**SPECIES**

Canine

**BREED**

Siberian Husky

**SEX**

F

**AGE**

4

**INTERPRETED BY**

Sebastian Schaub, DVM  
Dr. med. vet. DipECVDI

**HOSPITAL NAME**

JUANA DIAZ  
ANIMAL HOSPITAL

**REFERRING VET**

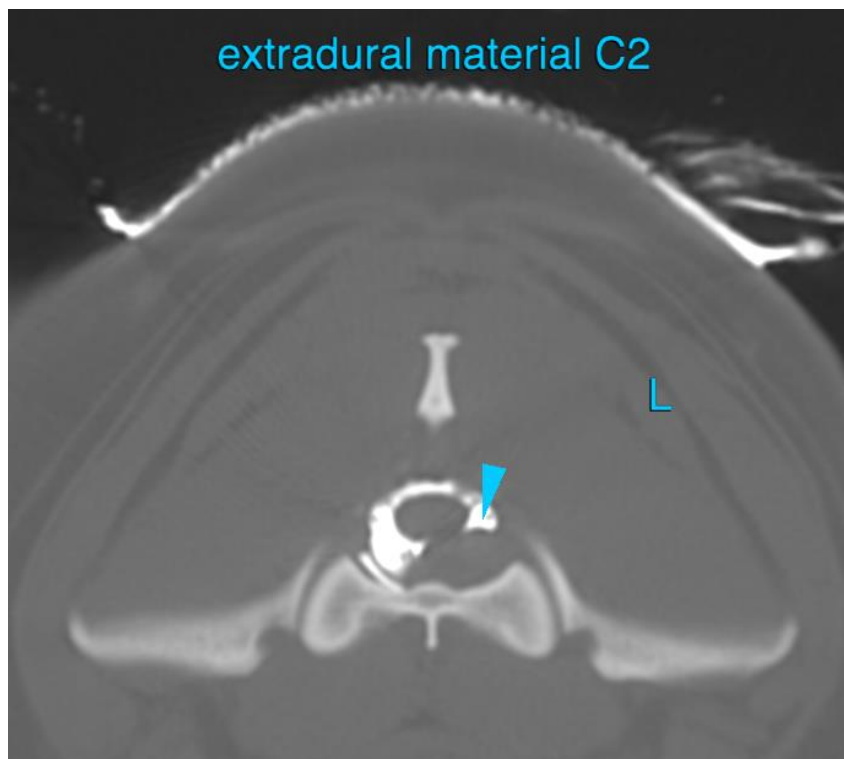
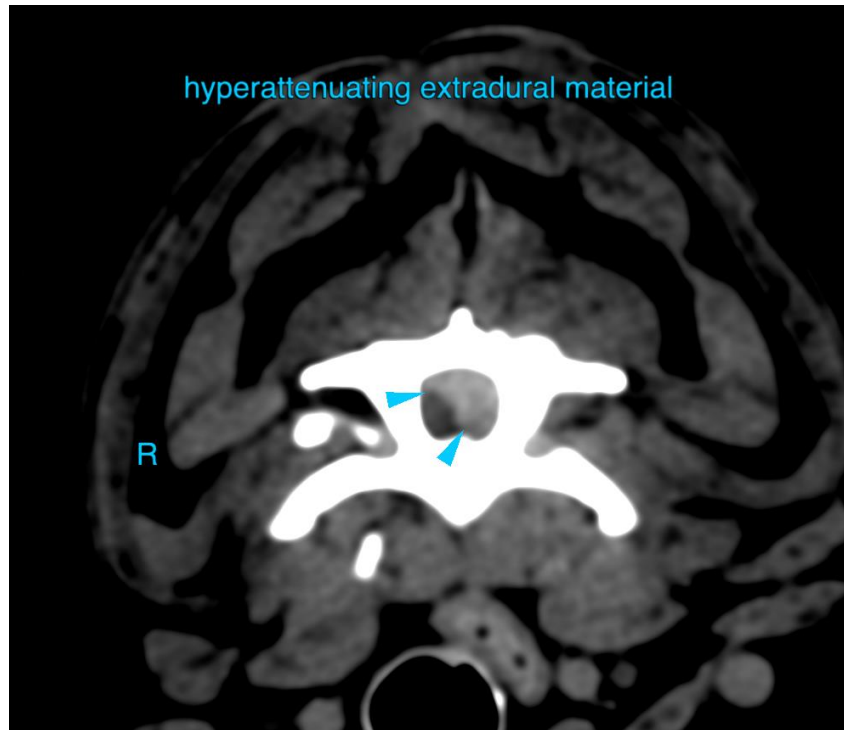
Rivera

**INVOICE**

52029

**DATE**

5-10-22





**PATIENT**

Luna Santiago

**SPECIES**

Canine

**BREED**

Siberian Husky

**SEX**

F

**AGE**

4

**INTERPRETED BY**

Sebastian Schaub, DVM  
Dr. med. vet. DipECVDI

**HOSPITAL NAME**

JUANA DIAZ  
ANIMAL HOSPITAL

**REFERRING VET**

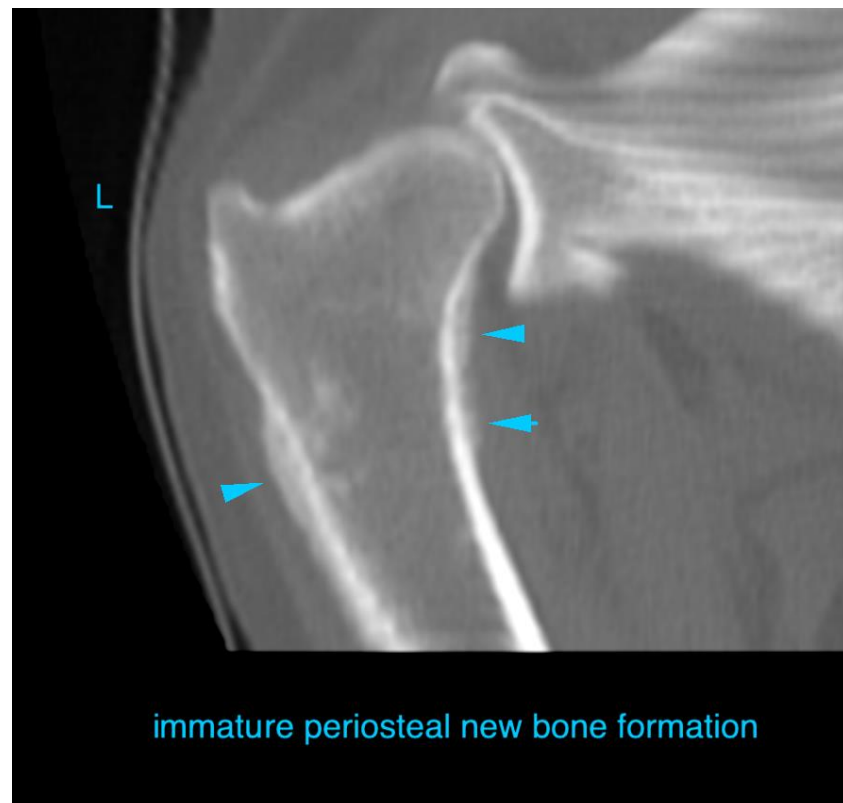
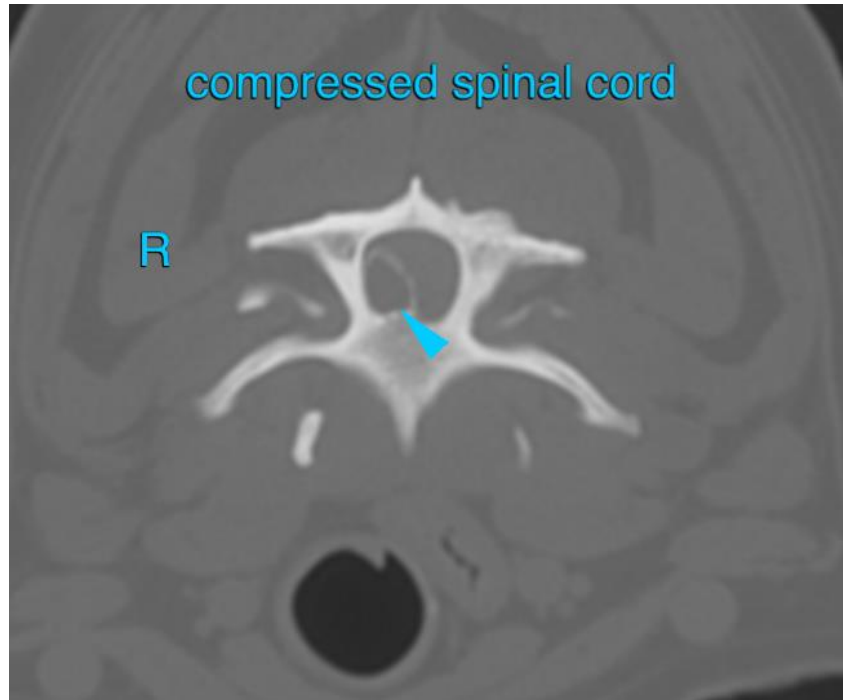
Rivera

**INVOICE**

52029

**DATE**

5-10-22





**PATIENT**

Luna Santiago

The information and recommendations provided are based on the images presented by the referring veterinarian/sonographer. No evaluation can be communicated regarding pathology that was not visible in the image/video clips provided.

**SPECIES**

Canine

Thank you for this referral. If the clinical or image interpretation does not parallel your findings or if I can be of any further assistance please contact me.

**BREED**

Siberian Husky

**Sebastian Schaub**, Sebastian Schaub, DVM, Dr. med. vet. DipECVDI  
sebast.schaub@gmail.com

**SEX**

F

**AGE**

4

**INTERPRETED BY**

Sebastian Schaub, DVM  
Dr. med. vet. DipECVDI

**HOSPITAL NAME**

JUANA DIAZ  
ANIMAL HOSPITAL

**REFERRING VET**

Rivera

**INVOICE**

52029

**DATE**

5-10-22