



PATIENT PRESENTING CLINICAL SIGNS

Sammy Sorise On/off Right front favoring/limping over the past week. VEG diagnosed pet with elbow dysplasia and a bone chip

SPECIES COMPUTED TOMOGRAPHY OF THE FRONT LIMBS

Canine A high resolution plain CT study of the front limbs is provided for review.

COMPUTED TOMOGRAPHIC FINDINGS

BREED The growth plates are age related open.

Bernadoodle Motion artefacts are appreciated level with the shoulder joints. The osseous and surrounding soft tissue structures of the shoulder joints are unremarkable.

SEX Both elbow joints present smooth osseous margins, the medial coronoid process of the elbow joints is well-defined and has a homogeneous density. The right elbow joint presents a radio-ulnar step formation, measuring 3.2 mm due to shortened right radius (10.3 cm right/11.6 cm left). The distal growth plate of the right radius is more mineralized in comparison to the contralateral radius. The left elbow joint presents a very mild radio-ulnar step formation of 0.9 mm.

Male

AGE The osseous and surrounding soft tissue structures of the carpal joints present no abnormalities.

7 Months

COMPUTED TOMOGRAPHIC DIAGNOSIS

INTERPRETED BY

Sebastian Schaub, DVM
Dr. med. vet. DipECVDI

- Right sided short radius and secondary significant incongruity of the right elbow joint
- Very mild radio-ulnar step formation left elbow joint
- Normal shoulder joints
- Normal carpal joints

HOSPITAL NAME

Animal Surgical
Center

INTERPRETATION OF THE FINDINGS & FURTHER RECOMMENDATIONS

The CT findings are consistent with right sided short radius due to premature closure of the distal growth plate – suspect preceding traumatic insult to the physis. The findings are a plausible explanation for the presenting clinical signs. Surgical management by the means of ulna-osteotomy/ostectomy is the therapy of choice – recommend discussing respective options with orthopedic surgeon.

REFERRING VET

All Creatures
Veterinary Services

INVOICE

58083

DATE

5-1-23



PATIENT

Sammy Sorise

SPECIES

Canine

BREED

Bernadoodle

SEX

Male

AGE

7 Months

INTERPRETED BY

Sebastian Schaub, DVM
Dr. med. vet. DipECVDI

HOSPITAL NAME

Animal Surgical
Center

REFERRING VET

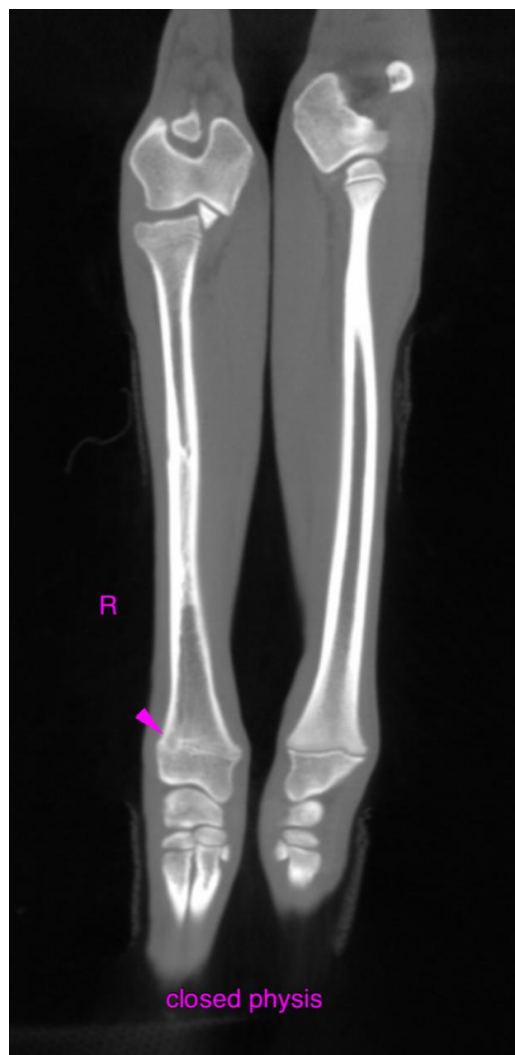
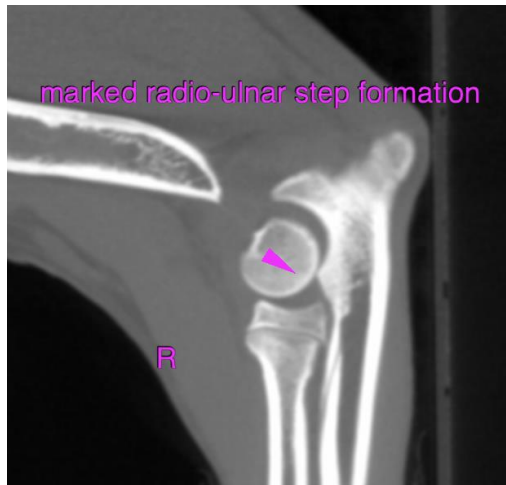
All Creatures
Veterinary Services

INVOICE

58083

DATE

5-1-23





PATIENT

Sammy Sorise

SPECIES The information and recommendations provided are based on the images presented by the referring veterinarian/sonographer. No evaluation can be communicated regarding pathology that was not visible in the image/video clips provided.

Canine

BREED

Thank you for this referral. If the clinical or image interpretation does not parallel your findings or if I can be of any further assistance please contact me.

Bernadoodle

Sebastian Schaub, Sebastian Schaub, DVM, Dr. med. vet. DipECVDI
sebast.schaub@gmail.com

SEX

Male

AGE

7 Months

INTERPRETED BY

Sebastian Schaub, DVM
Dr. med. vet. DipECVDI

HOSPITAL NAME

Animal Surgical
Center

REFERRING VET

All Creatures
Veterinary Services

INVOICE

58083

DATE

5-1-23