



## PATIENT

Rocco Brown

## SPECIES

Canine

## BREED

American Bulldog

## SEX

MN

## AGE

7Y

## WEIGHT

108lbs

## INTERPRETED BY

Sebastian Schaub, DVM  
Dr. med. vet.  
DipECVDI

## IMAGING PERFORMED BY

Tina Lynn,  
CVT/George  
Eales, DVM

## HOSPITAL NAME

Green Prairie Animal  
Hospital

## REFERRING VET

Highland Pet Hospital

## INVOICE

74543

## DATE

4-9-26

## PRESENTING CLINICAL SIGNS

Concern for cervical sialocele  
Swelling did respond to antibiotics  
Does have focal seizures

## COMPUTED TOMOGRAPHY OF THE SKULL

A high resolution pre- and post-contrast CT study of the skull is provided for review.

## COMPUTED TOMOGRAPHIC FINDINGS

The pictured parts of the dentition are complete.

Multifocal mild consolidation of the nasal cavity is appreciated.

Both temporomandibular joints present congruent joint spaces with even subchondral bone surfaces and are considered within normal limits.

Both tympanic bullae are aerated, the mucosal lining is not seen, the bony wall is smooth and thin. The external ear canals are within normal limits.

The brain presents no deviation from normal anatomy and symmetry. The brain parenchyma is homogeneous and within normal limits for attenuation and distribution of contrast enhancement. The ventricular system is non-dilated and symmetric.

The subcutaneous fat in the left submandibular region is swollen and presents moderate soft tissue striation.

The submandibular lymph nodes are prominent and have a mild irregular contrast enhancement pattern.

The mandibular salivary gland bilaterally reveals no abnormalities.

## COMPUTED TOMOGRAPHIC DIAGNOSIS

- Subcutaneous cellulitis left submandibular region
- Lymphadenopathy mandibular lymph nodes
- Very mild rhinitis

## INTERPRETATION OF THE FINDINGS & FURTHER RECOMMENDATIONS

The subcutaneous swelling in the submandibular region is caused by cellulitis and accompanying reactive lymphoid hyperplasia of the mandibular lymph nodes - I do not see signs of abscess formation nor evidence of sialocele.



## PATIENT

Rocco Brown

## SPECIES

Canine

## BREED

American Bulldog

## SEX

MN

## AGE

7Y

## WEIGHT

108lbs

## INTERPRETED BY

Sebastian Schaub, DVM  
Dr. med. vet.  
DipECVDI

## IMAGING PERFORMED BY

Tina Lynn,  
CVT/George  
Eales, DVM

## HOSPITAL NAME

Green Prairie Animal  
Hospital

## REFERRING VET

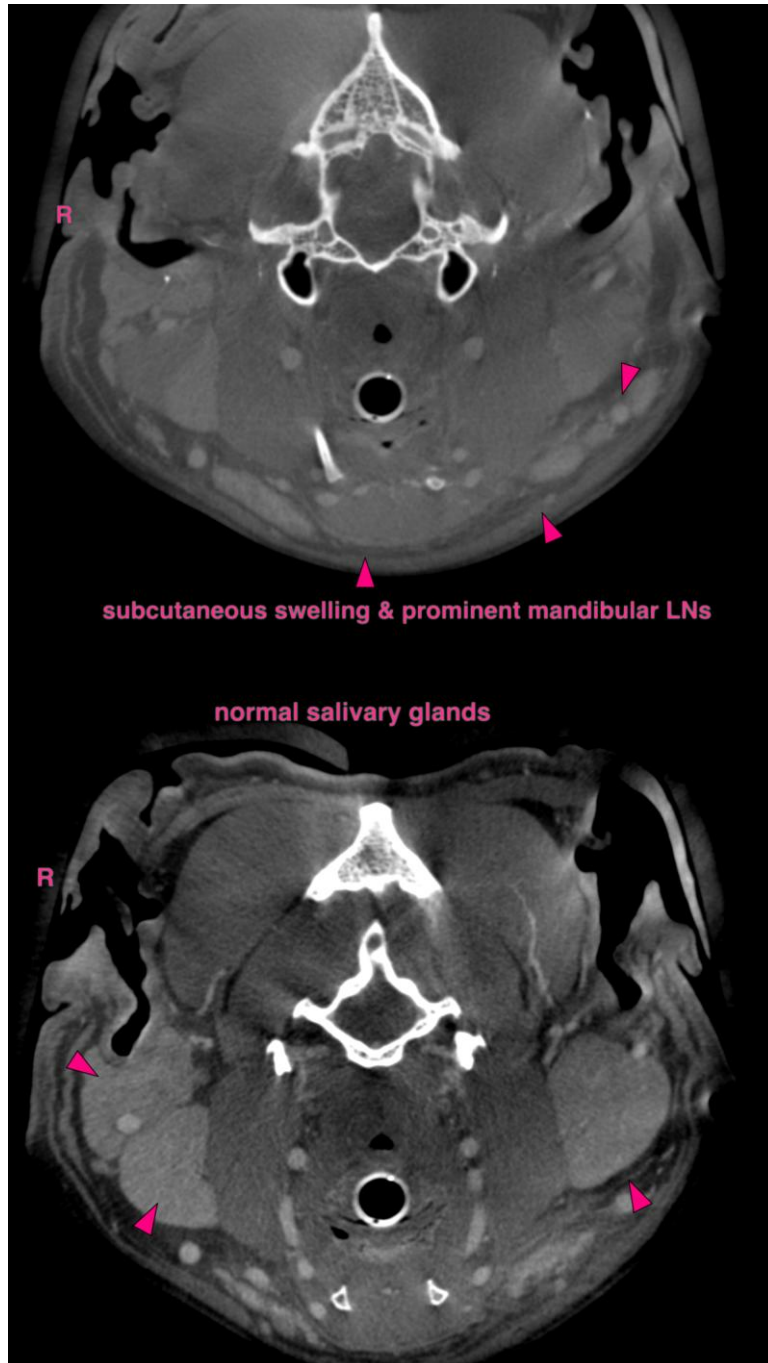
Highland Pet Hospital

## INVOICE

74543

## DATE

4-9-26





## PATIENT

Rocco Brown

## SPECIES

Canine

## BREED

American Bulldog

## SEX

MN

## AGE

7Y

## WEIGHT

108lbs

## INTERPRETED BY

Sebastian Schaub, DVM  
Dr. med. vet.  
DipECVDI

## IMAGING PERFORMED BY

Tina Lynn,  
CVT/George  
Eales, DVM

## HOSPITAL NAME

Green Prairie Animal  
Hospital

## REFERRING VET

Highland Pet Hospital

## INVOICE

74543

## DATE

4-9-26

The information and recommendations provided are based on the images presented by the referring veterinarian/sonographer. No evaluation can be communicated regarding pathology that was not visible in the image/video clips provided.

Thank you for this referral. If the clinical or image interpretation does not parallel your findings or if I can be of any further assistance please contact me.

**Sebastian Schaub**, Sebastian Schaub, DVM, Dr. med. vet. DipECVDI  
[info@sonopath.com](mailto:info@sonopath.com)