



PATIENT

Jack Bleiler

SPECIES

Canine

BREED

Lab

SEX

MN

AGE

7Y

WEIGHT

75.3lbs

INTERPRETED BY

Sebastian Schaub, DVM
Dr. med. vet.
DipECVDI

IMAGING PERFORMED BY

Amanda Mazzante,
CVT

HOSPITAL NAME

Williamsport West
Veterinary Hospital

REFERRING VET

Stephanie Daverio,
VMD

INVOICE

74545

DATE

4-9-26

PRESENTING CLINICAL SIGNS

2-month history of intermittent toe touching lameness on LH leg.
Stifle pain noted by O at home but no swelling or crepitus noted
No drawer sign on either side

COMPUTED TOMOGRAPHY OF THE PELVIS AND STIFLE JOINTS

A high resolution pre- and post-contrast CT study of the pelvis and stifle joints is provided for review.

COMPUTED TOMOGRAPHIC FINDINGS

The lumbosacral intervertebral disc is protruding into the left aspect of the vertebral canal, occupying approximately up to 90% of the height of the vertebral canal at the same level.

The osseous and surrounding soft tissue structures of the pelvis are within normal limits. Both coxofemoral joints present smooth osseous margins and congruent joint spaces.

In the subcutaneous tissue at the lateral aspect of the left thigh, a well-defined, uniform soft tissue attenuating nodule is seen; measuring 16 mm in diameter.

Both stifle joints have smooth margins of the periarticular bones and present without an intracapsular soft tissue swelling.

COMPUTED TOMOGRAPHIC DIAGNOSIS

- Left sided intervertebral disc herniation lumbosacral junction with possible compression of the left cauda equina fibers
- Non-specific subcutaneous nodule lateral aspect left thigh
- Normal pelvis & coxofemoral joints
- Normal stifle joints

INTERPRETATION OF THE FINDINGS & FURTHER RECOMMENDATIONS

The clinical relevance of the left sided intervertebral disc protrusion of the lumbosacral intervertebral disc is unclear but may be associated with compression of the left spinal nerve S1 that may be a source for pain and left hind limb lameness. No additional clinically relevant abnormalities are noted.



PATIENT

Jack Bleiler

SPECIES

Canine

BREED

Lab

SEX

MN

AGE

7Y

WEIGHT

75.3lbs

INTERPRETED BY

Sebastian Schaub, DVM
Dr. med. vet.
DipECVDI

IMAGING PERFORMED BY

Amanda Mazzante,
CVT

HOSPITAL NAME

Williamsport West
Veterinary Hospital

REFERRING VET

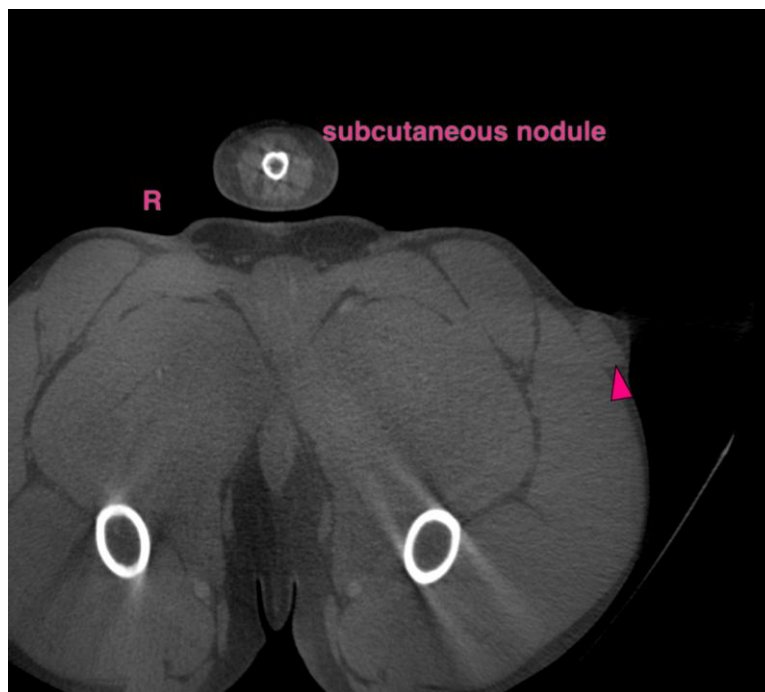
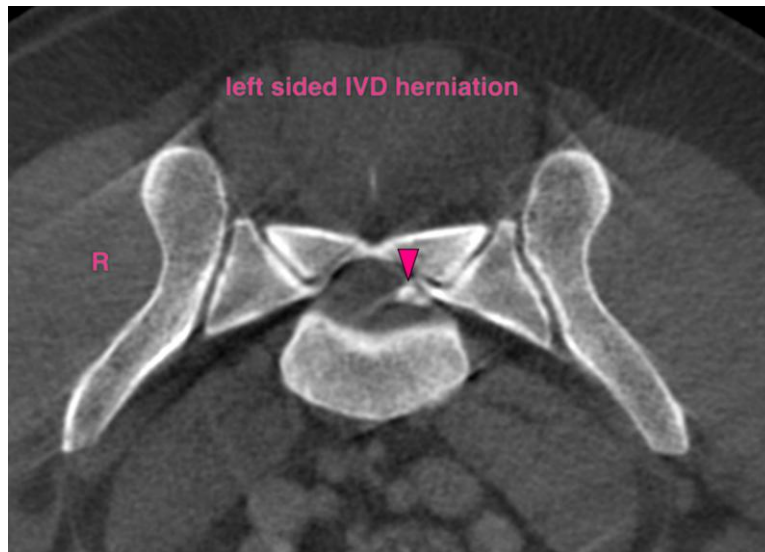
Stephanie Daverio,
VMD

INVOICE

74545

DATE

4-9-26





PATIENT

Jack Bleiler

SPECIES

Canine

BREED

Lab

SEX

MN

AGE

7Y

WEIGHT

75.3lbs

INTERPRETED BY

Sebastian Schaub, DVM
Dr. med. vet.
DipECVDI

IMAGING PERFORMED BY

Amanda Mazzante,
CVT

HOSPITAL NAME

Williamsport West
Veterinary Hospital

REFERRING VET

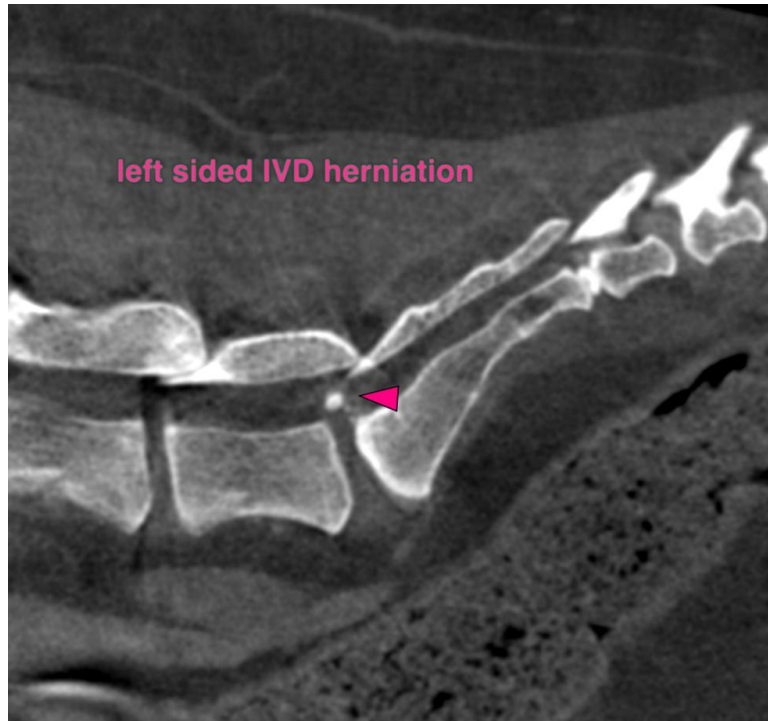
Stephanie Daverio,
VMD

INVOICE

74545

DATE

4-9-26



The information and recommendations provided are based on the images presented by the referring veterinarian/sonographer. No evaluation can be communicated regarding pathology that was not visible in the image/video clips provided.

Thank you for this referral. If the clinical or image interpretation does not parallel your findings or if I can be of any further assistance please contact me.

Sebastian Schaub, Sebastian Schaub, DVM, Dr. med. vet. DipECVDI
info@sonopath.com