



## PATIENT

Cooper Lazaro

## SPECIES

Canine

## BREED

Pomeranian

## SEX

Male

## AGE

10Y

## WEIGHT

5.7lbs

## INTERPRETED BY

Sebastian Schaub, DVM  
Dr. med. vet.  
DipECVDI

## IMAGING PERFORMED BY

NB

## HOSPITAL NAME

Green Dog Dental and  
Wellness

## REFERRING VET

Dr. Habawel

## INVOICE

74531

## DATE

4-9-26

## PRESENTING CLINICAL SIGNS

chest x-ray to evaluate for pulmonary metastasis

## RADIOGRAPHIC STUDY OF THE THORAX

Radiographs of the thorax in three imaging planes are provided for review.

## RADIOGRAPHIC FINDINGS

The vertebral endplates T5/T6 present mild spondylosis formation.

The extrathoracic soft tissues present homogeneous without abnormalities.

The heart is of normal size and shape; there is no evidence of cardiac chamber or vascular enlargement. The pulmonary vasculature is within normal limits.

The cranial mediastinum presents the expected soft tissue opacity. The mediastinal width is less than twice the width of the vertebral column at the same level.

The trachea is normal in diameter and presents the anticipated course. The luminal outline of the trachea is smooth.

The bronchial tree presents with thin walls and tapers uniformly towards the periphery as expected.

The lung parenchyma presents the expected architecture and opacity; the intrapulmonary vascular branching is seen up to the third order lung vessels.

The diaphragm is well delineated with even surface and the expected mild cranial bulging of the diaphragmatic cupola.

## RADIOGRAPHIC DIAGNOSIS

- Spondylosis deformans T5/T6

## INTERPRETATION OF THE FINDINGS & FURTHER RECOMMENDATIONS

The radiographic study is negative for pulmonary metastatic disease. No additional clinically relevant abnormalities are appreciated.



## PATIENT

Cooper Lazaro

## SPECIES

Canine

## BREED

Pomeranian

## SEX

Male

## AGE

10Y

## WEIGHT

5.7lbs

## INTERPRETED BY

Sebastian Schaub, DVM  
Dr. med. vet.  
DipECVDI

## IMAGING PERFORMED BY

NB

## HOSPITAL NAME

Green Dog Dental and  
Wellness

## REFERRING VET

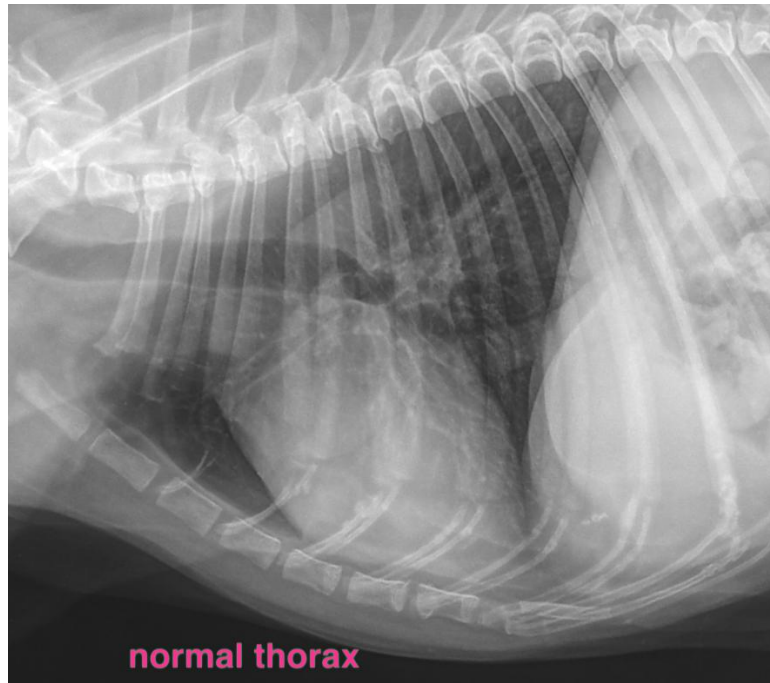
Dr. Habawel

## INVOICE

74531

## DATE

4-9-26



The information and recommendations provided are based on the images presented by the referring veterinarian/sonographer. No evaluation can be communicated regarding pathology that was not visible in the image/video clips provided.

Thank you for this referral. If the clinical or image interpretation does not parallel your findings or if I can be of any further assistance please contact me.

**Sebastian Schaub**, Sebastian Schaub, DVM, Dr. med. vet. DipECVDI  
[info@sonopath.com](mailto:info@sonopath.com)