



PATIENT

Warren Bohlen

SPECIES

Canine

BREED

Pitbull

SEX

Neutered Male

AGE

12Y

WEIGHT

27.6kg

INTERPRETED BY

Sebastian Schaub, DVM
Dr. med. vet.
DipECVDI

IMAGING PERFORMED BY

Aubrie

HOSPITAL NAME

CARE Surgery Center

REFERRING VET

Seth Bleakley

INVOICE

74525

DATE

4-8-26

PRESENTING CLINICAL SIGNS

Presented for removal of mass on prepuce. Metastasis check thoracic radiographs showed concern for lung nodule. CT scan of thorax and abdomen done for metastasis check

COMPUTED TOMOGRAPHY OF THE THORAX AND ABDOMEN

A high resolution pre- and post-contrast CT study of the thorax and abdomen is provided for review.

COMPUTED TOMOGRAPHIC FINDINGS

Thorax

Multifocal along the thoracolumbar junction moderate spondylosis formation is seen.

The sternal, cranial mediastinal and tracheobronchial lymph nodes are small elongated with a normal short-to-long-axis-ratio is < 0.5 , the attenuation and contrast enhancement pattern is uniform and considered within normal limits.

The cardiovascular structures including the pulmonary vasculature are within normal limits.

The bronchial tree presents with regular branching and tapers uniformly towards the periphery as expected, the bronchial walls are thin and smooth. The bronchus-to-artery ratio is within normal limits.

Multifocal throughout the lung parenchyma, well-defined soft tissue attenuating nodules are seen; measuring up to 13 mm in diameter.

Small incidental gas pockets are seen within the esophageal lumen; there is no evidence of abnormal dilation.

Abdomen

Both kidneys present within normal limits for size, shape and organ architecture. After contrast administration, a bilaterally symmetric and uniform nephro- and pyelogram is noted.

The adrenal glands are within normal limits for size, shape and organ architecture.

In the left liver lobes, a roundish, uniform soft tissue attenuating and irregular contrast enhancing mass is noted; measuring 6.9 cm in diameter. The parenchyma of the left division of the liver has a heterogeneous contrast enhancement pattern.

The cranial extremity of the spleen presents an irregular roundish mass with a uniform attenuating pattern and heterogeneous contrast uptake – mildly protruding beyond the splenic surface; measuring approximately 6.8 cm in diameter. The peritoneal fat surrounding the splenic mass presents mild soft tissue striation.

The pancreas is evenly contoured; the pancreatic parenchyma is homogeneous and presents uniform contrast enhancement.

The position, delineation, wall and content of the gastrointestinal tract are considered within normal limits throughout.

The bony and surrounding soft tissue structures reveal no abnormalities.

COMPUTED TOMOGRAPHIC DIAGNOSIS

- Splenic soft tissue mass
- Hepatic soft tissue mass and irregular contrast enhancement parenchyma left liver lobes



PATIENT

Warren Bohlen

SPECIES

Canine

BREED

Pitbull

SEX

Neutered Male

AGE

12Y

WEIGHT

27.6kg

INTERPRETED BY

Sebastian Schaub, DVM
Dr. med. vet.
DipECVDI

IMAGING PERFORMED BY

Aubrie

HOSPITAL NAME

CARE Surgery Center

REFERRING VET

Seth Bleakley

INVOICE

74525

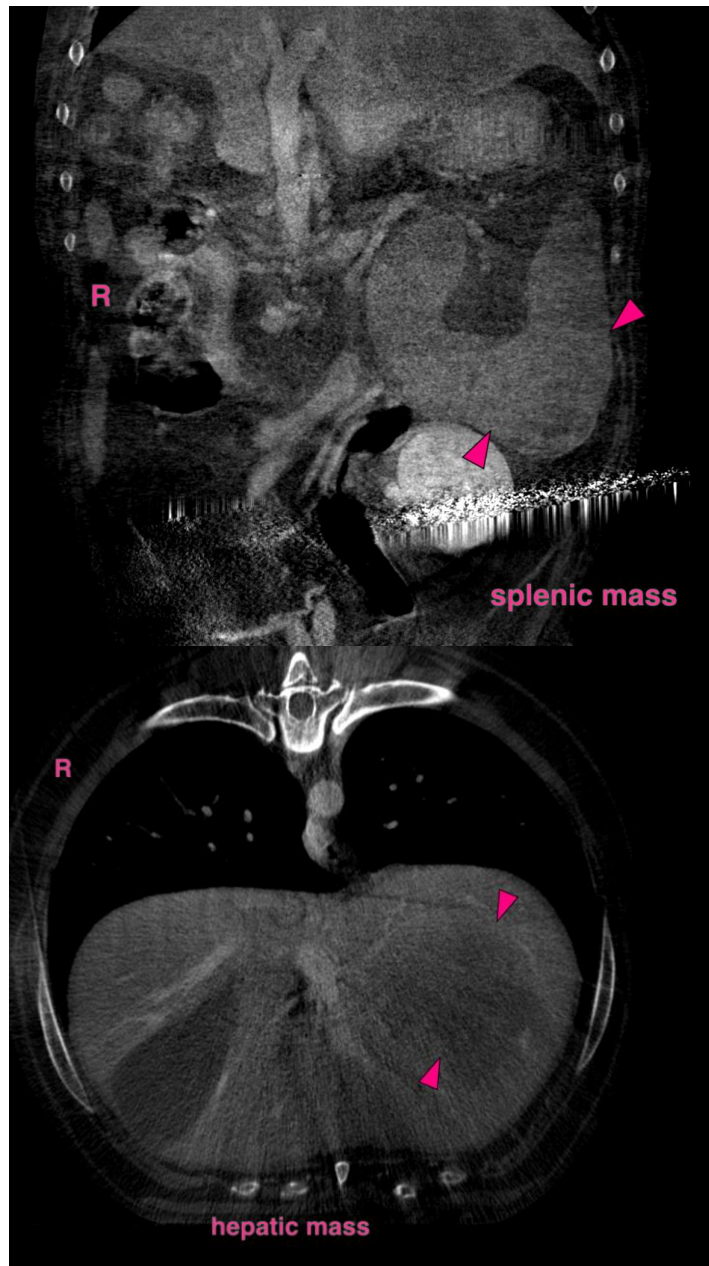
DATE

4-8-26

- Structured nodular interstitial lung pattern
- Spondylosis deformans

INTERPRETATION OF THE FINDINGS & FURTHER RECOMMENDATIONS

The CT findings are suggestive for disseminated neoplastic disease, presenting a splenic mass and hepatic mass along with pulmonary metastasis. Differentials can include hemangiosarcoma, carcinoma, other.





PATIENT

Warren Bohlen

SPECIES

Canine

BREED

Pitbull

SEX

Neutered Male

AGE

12Y

WEIGHT

27.6kg

INTERPRETED BY

Sebastian Schaub, DVM
Dr. med. vet.
DipECVDI

IMAGING PERFORMED BY

Aubrie

HOSPITAL NAME

CARE Surgery Center

REFERRING VET

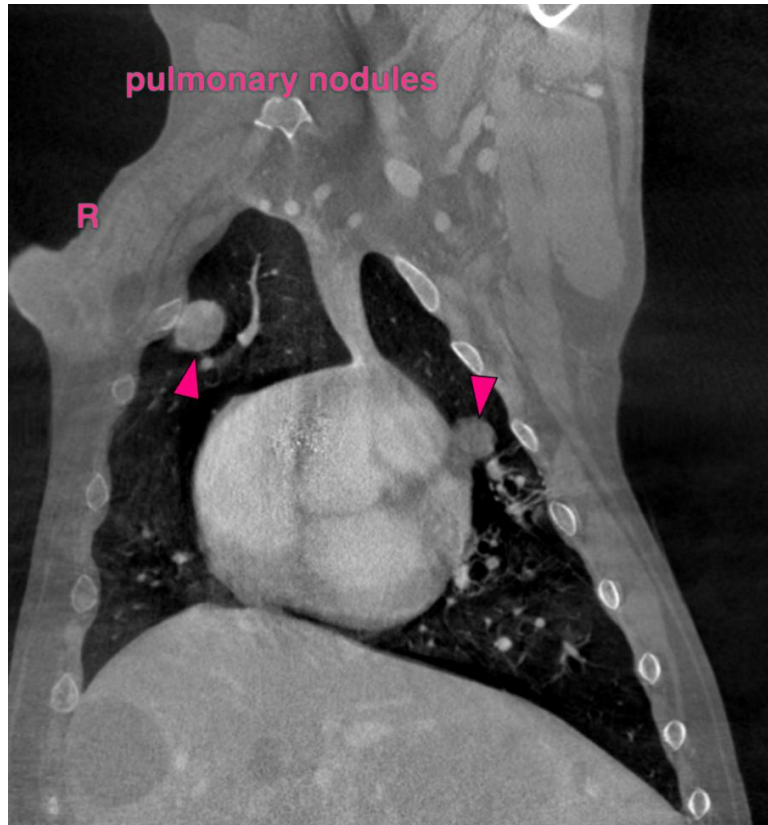
Seth Bleakley

INVOICE

74525

DATE

4-8-26



The information and recommendations provided are based on the images presented by the referring veterinarian/sonographer. No evaluation can be communicated regarding pathology that was not visible in the image/video clips provided.

Thank you for this referral. If the clinical or image interpretation does not parallel your findings or if I can be of any further assistance please contact me.

Sebastian Schaub, Sebastian Schaub, DVM, Dr. med. vet. DipECVDI
info@sonopath.com