



PATIENT PRESENTING CLINICAL SIGNS

Phoenix Veek Phoenix presents to SOVSC for further evaluation of progressive ophthalmic concerns. He has had KCS, ulceration, and ophthalmic discharge issues for 2 years but more recently there has been OS buphthalmia and discomfort. Recent assessment by a veterinary ophthalmologist showed concern for restrictive orbital conditions and further evaluation recommended. His preanesthetic labwork was stable and he has no additional concurrent concerns.

SPECIES

Feline

COMPUTED TOMOGRAPHY OF THE SKULL

A high resolution pre- and post-contrast CT study of the skull is provided for review.

BREED

Domestic Medium Hair

COMPUTED TOMOGRAPHIC FINDINGS

The tooth elements 101, 103, 106-109, 201, 203, 407 and 409 are absent. The alveolar process of the right maxillary bone presents advanced proliferative osseous remodeling with well-defined margins.

Mild destruction of the left nasal conchal structures is appreciated.

SEX

Male

The left ocular bulb is encompassed by an ill-defined, uniform soft tissue attenuating and irregular contrast enhancing soft tissue proliferation. The left ocular bulb is distorted and displaced rostrally and dorsally by the mass effect.

AGE

11

Both temporomandibular joints present congruent joint spaces with even subchondral bone surfaces and are considered within normal limits.

The volume of the right tympanic bulla is increased and the wall is irregularly thickened and multifocal moth eaten osteolytic lesions are appreciated. The inner ear bilaterally presents no abnormalities of the osseous labyrinth. The external ear canals are within normal limits.

INTERPRETED BY

Sebastian Schaub, DVM
Dr. med. vet. DipECVDI

The brain presents no deviation from normal anatomy and symmetry. The brain parenchyma is homogeneous and within normal limits for attenuation and distribution of contrast enhancement. The ventricular system is non-dilated and symmetric.

HOSPITAL NAME

Southern Oregon
Veterinary Specialty
Center

The left parotid lymph node is prominent.

The submandibular and medial retropharyngeal lymph nodes are small and elongated with a normal short-to-long-axis-ratio is < 0.5, the attenuation and contrast enhancement pattern is uniform.

COMPUTED TOMOGRAPHIC DIAGNOSIS

REFERRING VET

Dr. Rory Applegate

- Ill-defined soft tissue mass in left orbital cavity encompassing left ocular bulb
- Secondary left sided exophthalmos
- Lymphadenopathy left parotid lymph node
- Right sided chronic otitis media
- Mild destructive rhinitis
- Advanced osseous remodeling alveolar process right maxillary bone due to preceding periodontal disease
- Multiple absent teeth

INVOICE

57694

INTERPRETATION OF THE FINDINGS & FURTHER RECOMMENDATIONS

DATE

4-8-23

The soft tissue mass in the left orbital cavity, encompassing the left ocular bulb is highly suggestive for feline restrictive orbital myofibroblastic sarcoma (FROMS). Other potentials can include melanoma, lymphosarcoma, myxosarcoma, other. Complete surgical excision of the mass by left orbital



PATIENT exenteration can be tried, but the mass is extending caudally up to the level of the orbital fissure and reoccurrence is likely.

Phoenix Veek

The prominent parotid lymph node is equivocal for reactive hyperplasia or metastatic disease.

SPECIES

Feline

BREED

Domestic Medium
Hair

SEX

Male

AGE

11

INTERPRETED BY

Sebastian Schaub, DVM
Dr. med. vet. DipECVDI

HOSPITAL NAME

Southern Oregon
Veterinary Specialty
Center

REFERRING VET

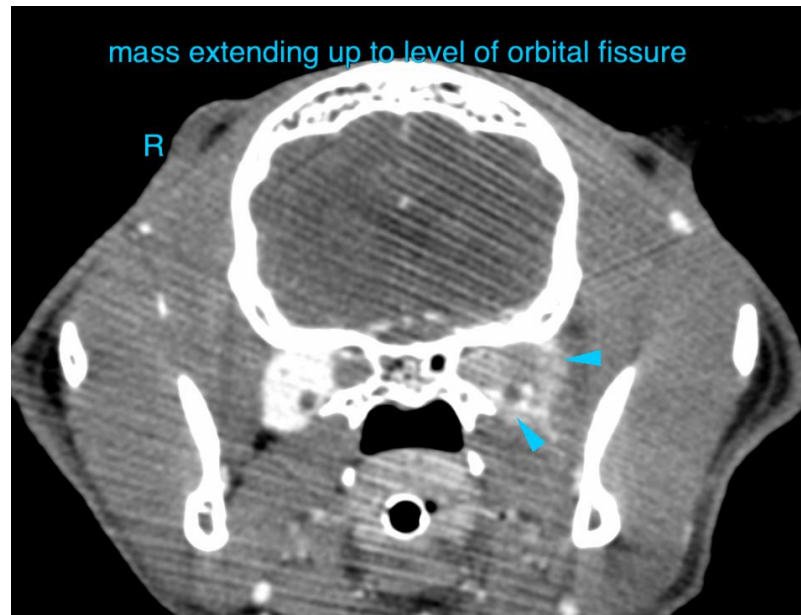
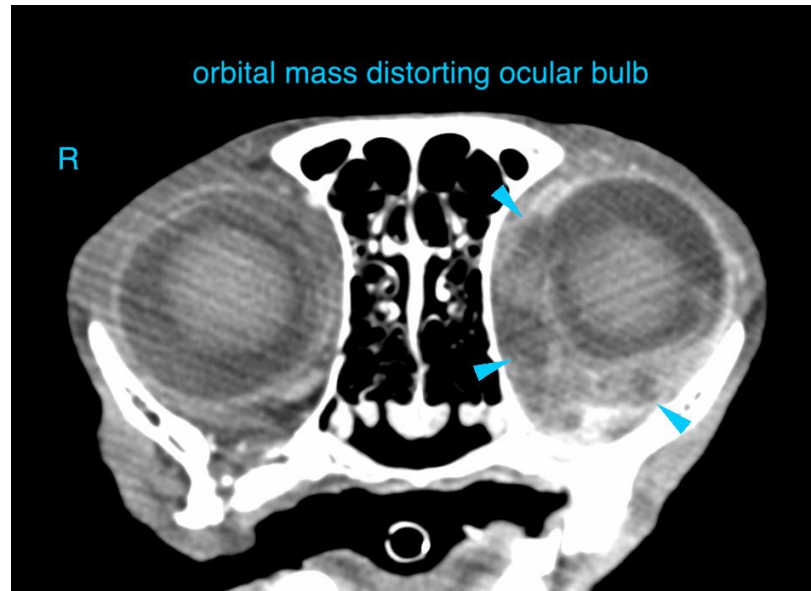
Dr. Rory Applegate

INVOICE

57694

DATE

4-8-23





PATIENT

Phoenix Veek

SPECIES

Feline

BREED

Domestic Medium
Hair

SEX

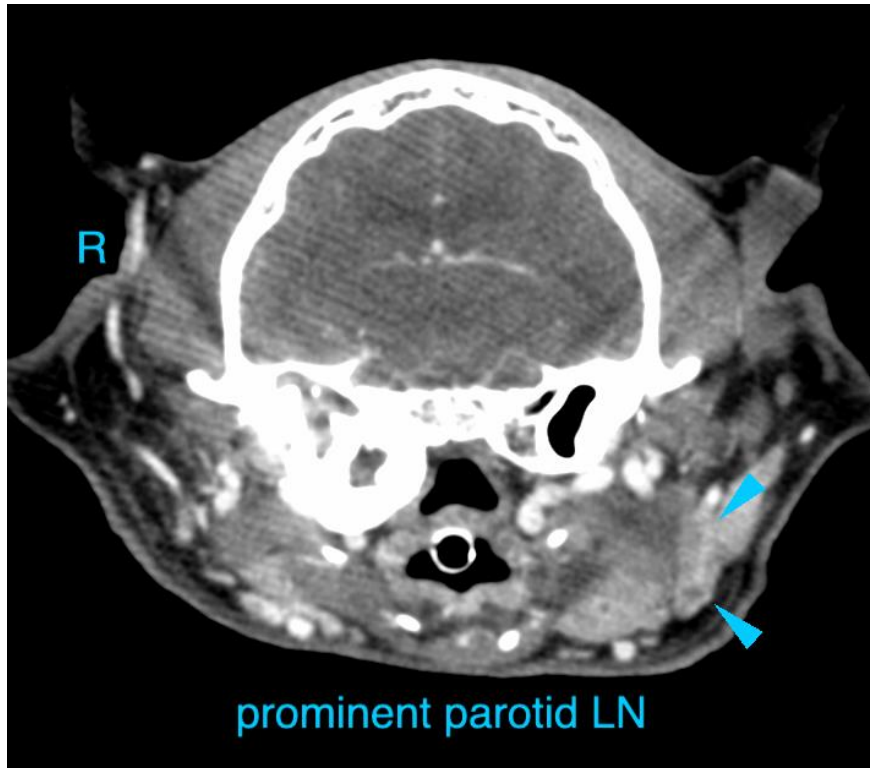
Male

AGE

11

INTERPRETED BY

Sebastian Schaub, DVM
Dr. med. vet. DipECVDI



HOSPITAL NAME

Southern Oregon
Veterinary Specialty
Center

REFERRING VET

Dr. Rory Applegate

INVOICE

57694

DATE

4-8-23

The information and recommendations provided are based on the images presented by the referring veterinarian/sonographer. No evaluation can be communicated regarding pathology that was not visible in the image/video clips provided.

Thank you for this referral. If the clinical or image interpretation does not parallel your findings or if I can be of any further assistance please contact me.

Sebastian Schaub, Sebastian Schaub, DVM, Dr. med. vet. DipECVDI
sebast.schaub@gmail.com