



**PATIENT PRESENTING CLINICAL SIGNS**

Taika Trottier coughing for the last 2 months. Indoor cat Eating well Has a grade IV systolic murmur  
Abnormal PE/Chem/CBC/UA Results: Mild eosinophilia on CBC

**SPECIES RADIOGRAPHIC STUDY OF THE THORAX**

Feline Radiographs of the thorax in three imaging planes are provided for review.

**RADIOGRAPHIC FINDINGS**

**BREED**

DSH The surrounding bony structures are within normal limits.  
The extrathoracic soft tissues present homogeneous without abnormalities.

**SEX**

The heart is of normal size and shape, there is no evidence of cardiac chamber or vascular enlargement. The pulmonary vasculature is within normal limits.

**MN**

The trachea is normal in diameter and presents the anticipated course. The luminal outline of the trachea is smooth.

**AGE**

2 Years Generalized moderate peribronchial cuffing of the bronchial walls is appreciated.

**INTERPRETED BY**

Sebastian Schaub, DVM  
Dr. med. vet. DipECVDI

The lung parenchyma presents the expected architecture and opacity; the intrapulmonary vascular branching is seen up to the third order lung vessels.

The diaphragm is well delineated with even surface and the expected mild cranial bulging of the diaphragmatic cupola.

**RADIOGRAPHIC DIAGNOSIS**

- Moderate bronchial lung pattern

**HOSPITAL NAME**

Balmy Beach Pet Hospital

**INTERPRETATION OF THE FINDINGS & FURTHER RECOMMENDATIONS**

The pulmonary changes are compatible with an inflammatory lower airway disease, underlying feline bronchial disease ('feline asthma') ± bacterial/viral superinfection is considered most likely. Bronchoscopy including BAL or a transtracheal wash can be used as advanced diagnostic tests.

**REFERRING VET**

Dr. Singh

No overt abnormalities of the heart are appreciated. Anyway, a cardiac echo would be ideal for further assessment of cardiac chamber size and function and workup of the cardiac murmur.

**INVOICE**

51418

**DATE**

4-8-22



**PATIENT**

Taika Trottier

**SPECIES**

Feline

**BREED**

DSH

**SEX**

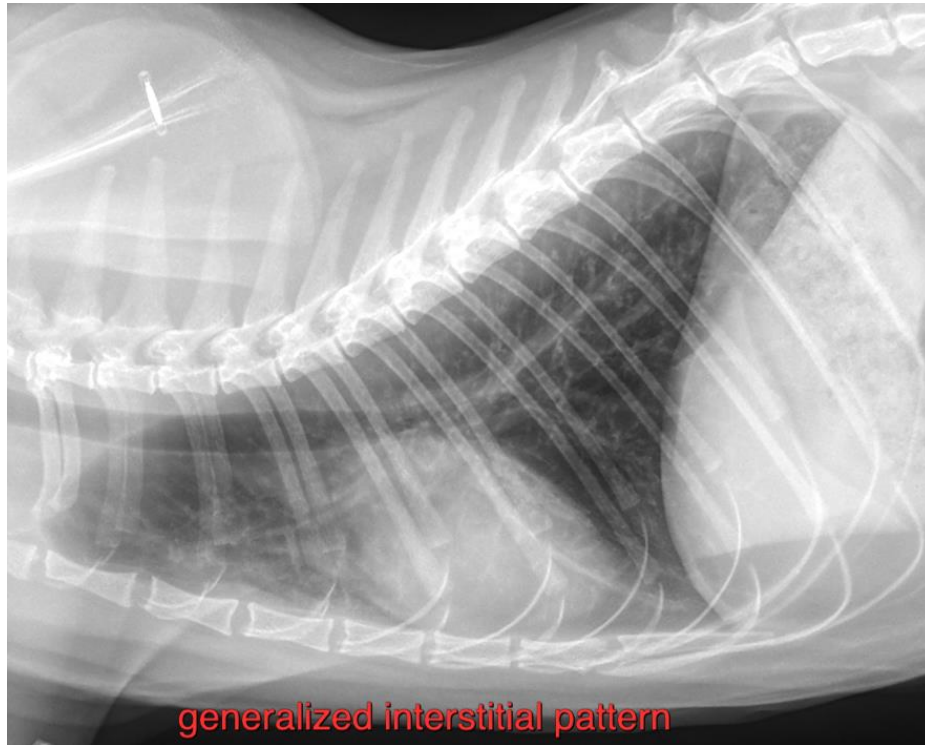
MN

**AGE**

2 Years

**INTERPRETED BY**

Sebastian Schaub, DVM  
Dr. med. vet. DipECVDI



**HOSPITAL NAME**

Balmy Beach Pet  
Hospital

**REFERRING VET**

Dr. Singh

**INVOICE**

51418

**DATE**

4-8-22

The information and recommendations provided are based on the images presented by the referring veterinarian/sonographer. No evaluation can be communicated regarding pathology that was not visible in the image/video clips provided.

Thank you for this referral. If the clinical or image interpretation does not parallel your findings or if I can be of any further assistance please contact me.

**Sebastian Schaub**, Sebastian Schaub, DVM, Dr. med. vet. DipECVDI  
sebast.schaub@gmail.com