



**PATIENT PRESENTING CLINICAL SIGNS**

Romeo Brooker History: P presents for limping on R hind leg. o states p was holding leg up last Saturday, did not see p injure himself.

**SPECIES RADIOGRAPHIC STUDY OF THE PELVIS AND STILFE JOINTS**

Canine A ventrodorsal projection of the pelvis and craniocaudal & lateral projection of the stifle joints is provided for review.

**BREED RADIOGRAPHIC FINDINGS**

German Shepherd Both coxofemoral joints present moderate to marked osteophyte new bone formation, R>L. The right acetabular groove is shallow, and the right femoral head is misshapen by the chronic osteophyte formation.

**SEX**

Neutered Male A TPLO implant is seen at the proximomedial aspect of the left tibia; the osteotomy is completely filled with trabecular bone. The periarticular bones of the left stifle joint present moderate osteophyte new bone formation and a mild intracapsular soft tissue swelling is seen.

**AGE**

6 Years 10 Months The right stifle joint presents smooth osseous margins. The infrapatellar fat pad of the right stifle joints presents a mild soft tissue striation.

**RADIOGRAPHIC DIAGNOSIS**

**INTERPRETED BY**

Sebastian Schaub,  
DVM Dr. med. vet.  
DipECVDI

- Advanced degenerative osteoarthritis coxofemoral joints bilaterally, R>L, due to hip dysplasia
- Equivocal articular swelling right stifle joint
- History of left sided cranial cruciate rupture and surgical management by TPLO – the osteotomy is in the remodeling phase

**HOSPITAL NAME**

DPC Veterinary H

**INTERPRETATION OF THE FINDINGS & FURTHER RECOMMENDATIONS**

The main finding of the right hind limb are the advanced degenerative changes of the right coxofemoral joint. Rule out acute on chronic insult that might have triggered pain with subsequent lameness.

**REFERRING VET**

Dr. Rivera

The right stifle joint presents with equivocal joint effusion – check if a positive drawer sign or tibial compression test is present.

**TECHNICAL COMMENTS**

**INVOICE**

14647

A gloved human hand is seen in the primary beam, please consider radiation safety guidelines!

**DATE**

4/8/22



**PATIENT**

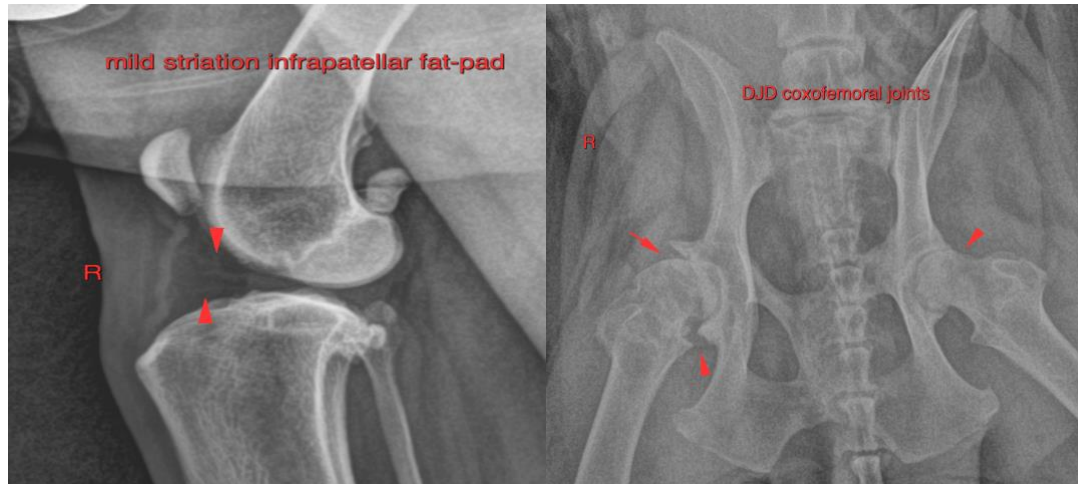
Romeo Brooker

**SPECIES**

Canine

**BREED**

German Shepherd



**SEX**

Neutered Male

**The information and recommendations provided are based on the images presented by the referring veterinarian/sonographer. No evaluation can be communicated regarding pathology that was not visible in the image/video clips provided.**

**AGE**

6 Years 10 Months

Thank you for this referral. If the clinical or image interpretation does not parallel your findings or if I can be of any further assistance please contact me.

**INTERPRETED BY**

**Sebastian Schaub**, Sebastian Schaub, DVM, Dr. med. vet. DipECVDI  
sebast.schaub@gmail.com

Sebastian Schaub,  
DVM Dr. med. vet.  
DipECVDI

**HOSPITAL NAME**

DPC Veterinary H

**REFERRING VET**

Dr. Rivera

**INVOICE**

14647

**DATE**

4/8/22