



PATIENT

Lola Shepherd

SPECIES

Canine

BREED

Chihuahua Mix

SEX

Female Spayed

AGE

6/1/2012

WEIGHT

16.26lbs

INTERPRETED BY

Sebastian Schaub, DVM
Dr. med. vet.
DipECVDI

IMAGING PERFORMED BY

Cottage Grove
Veterinary Clinic

HOSPITAL NAME

Cottage Grove
Veterinary Clinic

REFERRING VET

Damewood

INVOICE

74497

DATE

4-7-26

PRESENTING CLINICAL SIGNS

- Met check
- Splenic & Liver tumors
- Coughing

RADIOGRAPHIC STUDY OF THE THORAX

Radiographs of the thorax in three imaging planes are provided for review.

RADIOGRAPHIC FINDINGS

Multifocal along the thoracic spine mild spondylosis formation is seen. The costochondral junction presents moderate degenerative changes.

The extrathoracic soft tissues present homogeneous without abnormalities.

The heart is of normal size and shape; there is no evidence of cardiac chamber or vascular enlargement. The pulmonary vasculature is within normal limits.

The cranial mediastinum presents the expected soft tissue opacity. The mediastinal width is less than twice the width of the vertebral column at the same level.

The trachea is normal in diameter and presents the anticipated course. The luminal outline of the trachea is smooth.

The bronchial tree presents with thin walls and tapers uniformly towards the periphery as expected.

The lung parenchyma presents the expected architecture and opacity; the intrapulmonary vascular branching is seen up to the third order lung vessels.

The diaphragm is well delineated with even surface and in a relative cranial position due to an abdominal mass effect – history of hepatic and splenic masses.

RADIOGRAPHIC DIAGNOSIS

- History of hepatic soft tissue mass
- No evidence of pulmonary metastatic disease
- Spondylosis deformans

INTERPRETATION OF THE FINDINGS & FURTHER RECOMMENDATIONS

The radiographic study is negative for metastatic disease.



PATIENT

Lola Shepherd

SPECIES

Canine

BREED

Chihuahua Mix

SEX

Female Spayed

AGE

6/1/2012

WEIGHT

16.26lbs

INTERPRETED BY

Sebastian Schaub, DVM
Dr. med. vet.
DipECVDI

IMAGING PERFORMED BY

Cottage Grove
Veterinary Clinic

HOSPITAL NAME

Cottage Grove
Veterinary Clinic

REFERRING VET

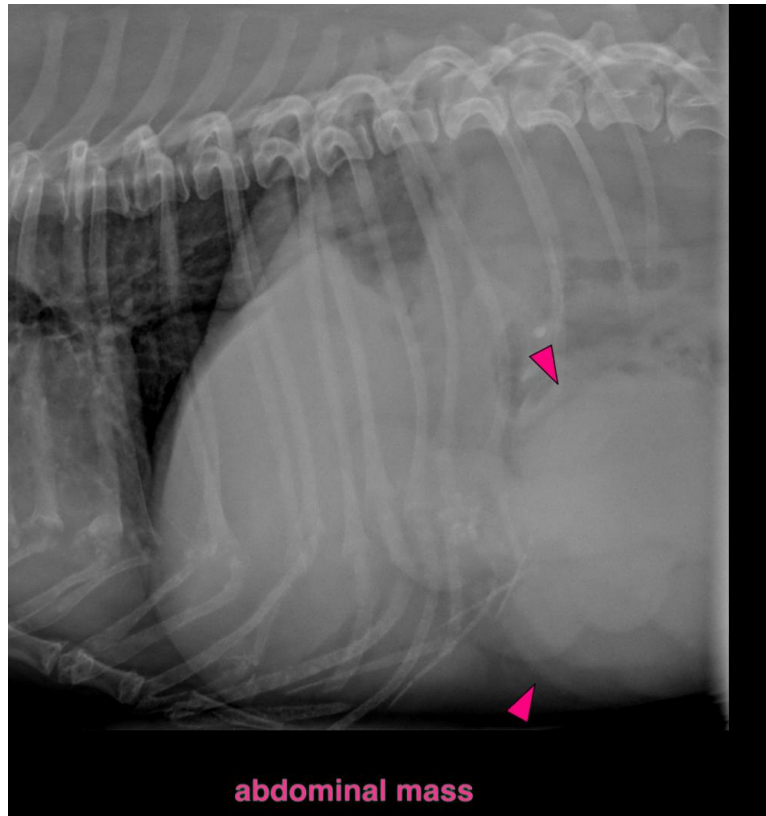
Damewood

INVOICE

74497

DATE

4-7-26



The information and recommendations provided are based on the images presented by the referring veterinarian/sonographer. No evaluation can be communicated regarding pathology that was not visible in the image/video clips provided.

Thank you for this referral. If the clinical or image interpretation does not parallel your findings or if I can be of any further assistance please contact me.

Sebastian Schaub, Sebastian Schaub, DVM, Dr. med. vet. DipECVDI
info@sonopath.com