



PATIENT

Athena Marqua

SPECIES

Canine

BREED

Mastiff

SEX

SF

AGE

9Y

WEIGHT

135lbs

INTERPRETED BY

Sebastian Schaub, DVM
Dr. med. vet.
DipECVDI

IMAGING PERFORMED BY

Jen Amidon

HOSPITAL NAME

The Pet Hospital of
Stratford

REFERRING VET

Dr. Bashkin

INVOICE

74491

DATE

4-7-26

PRESENTING CLINICAL SIGNS

Post cystotomy xrays

RADIOGRAPHIC STUDY OF THE ABDOMEN

Two lateral views of the caudal abdomen are provided for review.

RADIOGRAPHIC FINDINGS

The vertebral endplates L7/S1 present advanced spondylosis formation.

In the subcutaneous fat at the caudoventral abdominal wall, multiple gas inclusions are visible.

The serosal detail is maintained throughout the peritoneal and retroperitoneal space.

The splenic body and tail are considered normal for position, size, shape and opacity.

Both kidneys are seen and present with normal size, shape, delineation and opacity. The urinary bladder is in its anticipated position, and two gas bubbles are superimposed on the urinary bladder. No radiopaque calculi are noted throughout the upper and lower urinary tract. The peritoneal fat ventral to the urinary bladder presents mild to moderate soft tissue striation.

The small intestinal loops are of even diameter and non-dilated, a small amount of gas is seen within the small intestinal loops and considered within normal limits.

The colon is seen in the expected position and presents with appropriate content.

RADIOGRAPHIC DIAGNOSIS

- Preceding cystotomy with mild subcutaneous emphysema caudoventral abdominal wall and small amount of gas in the urinary bladder
- Spondylosis deformans

INTERPRETATION OF THE FINDINGS & FURTHER RECOMMENDATIONS

The radiographic study reveals a normal state post cystotomy. No radiopaque calculi are appreciated throughout the lower urinary tract.



PATIENT

Athena Marqua

SPECIES

Canine

BREED

Mastiff

SEX

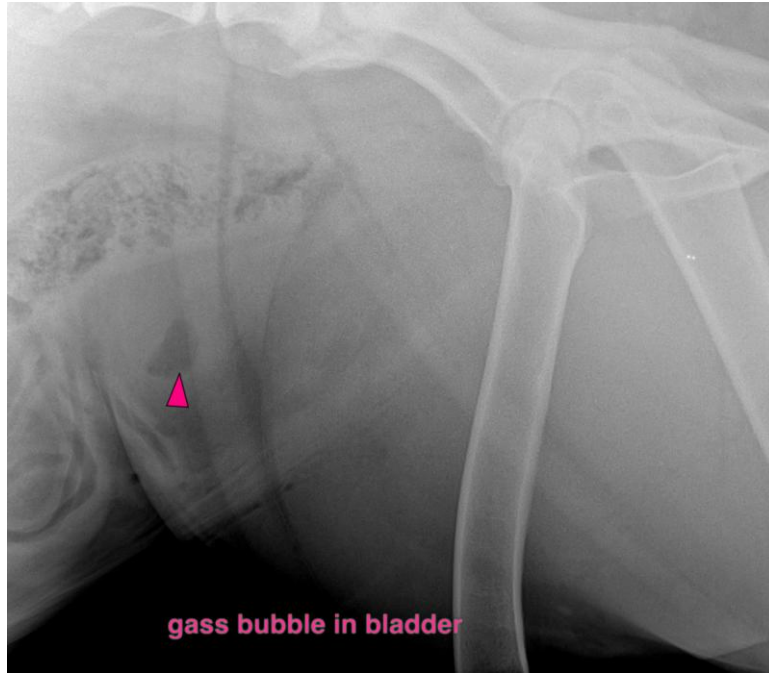
SF

AGE

9Y

WEIGHT

135lbs



INTERPRETED BY

Sebastian Schaub, DVM
Dr. med. vet.
DipECVDI

IMAGING PERFORMED BY

Jen Amidon

HOSPITAL NAME

The Pet Hospital of
Stratford

REFERRING VET

Dr. Bashkin

INVOICE

74491

DATE

4-7-26

The information and recommendations provided are based on the images presented by the referring veterinarian/sonographer. No evaluation can be communicated regarding pathology that was not visible in the image/video clips provided.

Thank you for this referral. If the clinical or image interpretation does not parallel your findings or if I can be of any further assistance please contact me.

Sebastian Schaub, Sebastian Schaub, DVM, Dr. med. vet. DipECVDI
info@sonopath.com