



PATIENT PRESENTING CLINICAL SIGNS

Bug Camomile History: Chronic intermittent vomiting, otherwise WNL
 Abnormal PE/Chem/CBC/UA Results: Elevated ALP, hypoalbuminemia

SPECIES

Feline

COMPUTED TOMOGRAPHIC STUDY OF THE ABDOMEN

A high resolution pre- and post-contrast CT study of the abdomen is provided for review.

BREED

COMPUTED TOMOGRAPHIC FINDINGS

DLH

A mild to moderate amount of fluid attenuating material is seen in the peritoneal cavity and the peritoneal fat presents mild fat-stranding. Multiple small (<4 mm) contrast enhancing nodular lesions are seen in the peritoneal cavity, accentuated in the left cranial abdominal quadrant.

SEX

Neutered Male

The cranial pole of the right kidney presents a concave depression of the dorsal surface.

The adrenal glands are within normal limits for size, shape and organ architecture.

AGE

12

The liver presents with normal shape, even surface, uniformly attenuating parenchyma. Post contrast administration, in the hilar region of the right lateral liver lobe, a heterogeneous hypoattenuating lesion, measuring 16 x 12 x 11 mm is noted.

INTERPRETED BY

Sebastian Schaub,
 DVM Dr. med. vet.
 DipECVDI

The body of the spleen presents a homogeneous soft tissue attenuating and heterogeneous contrast enhancing spherical mass, protruding beyond the visceral splenic surface, measuring 2.9 x 2.2 x 2.6 cm in size. Medial margin of the splenic mass is ill-defined and confluent with the surrounding fluid attenuating material. The cranial extremity of the spleen presents an intraparenchymal, post contrast mild hypoattenuating nodule, measuring 8 mm in diameter.

HOSPITAL NAME

Scottsdale VC

The splenic lymph node is prominent.

The pancreas is evenly contoured, the pancreatic parenchyma is homogeneous and presents uniform contrast enhancement.

REFERRING VET

Dr. Magnussen

The pancreatic duct and the common bile duct are dilated measuring up to 2.4 mm in diameter.

The position, delineation, wall and content of the gastrointestinal tract are considered within normal limits throughout.

INVOICE

21921

The bony and surrounding soft tissue structures reveal no abnormalities.

COMPUTED TOMOGRAPHIC DIAGNOSIS

- Splenic mass with signs of laceration of the surface

DATE

4/7/23



PATIENT

Bug Camomile

- Splenic nodule
- Hepatic intraparenchymal nodular lesion
- Multiple peritoneal contrast enhancing nodules – accentuated in the region of the splenic mass
- Lymphadenopathy splenic lymph node
- Moderate peritoneal effusion

SPECIES

Feline

- Mild dilation pancreatic duct and common bile duct without signs of mechanical obstruction – considered as an age related finding
- Right sided chronic renal infarct

INTERPRETATION OF THE FINDINGS & FURTHER RECOMMENDATIONS

BREED

DLH

The CT study is consistent with splenic soft tissue neoplasia with signs of laceration of the mass and secondary peritoneal effusion – suspect peritoneal hemorrhage. Potentials include hemangiosarcoma, hemangioma, round cell tumor, sarcoma of different origin. The small peritoneal nodular lesions and the hepatic mass are highly suggestive for metastatic spread. Splenectomy is considered as the the therapy of choice, although it might only be a palliative treatment option.

SEX

Neutered Male

AGE

12

INTERPRETED BY

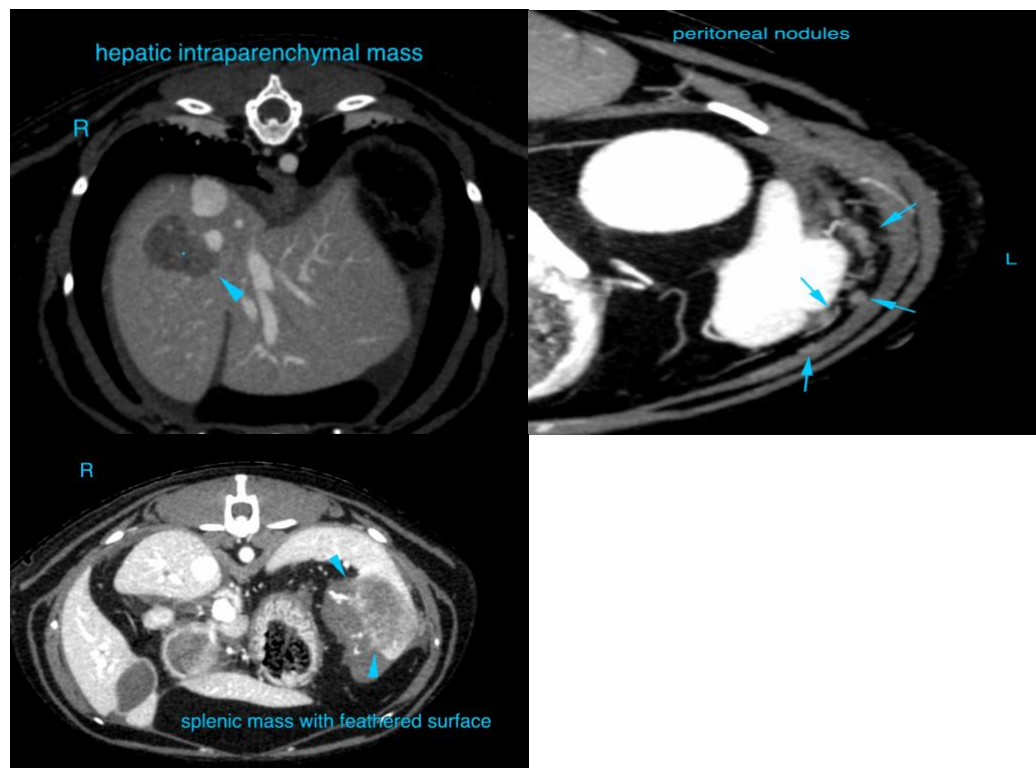
Sebastian Schaub,
DVM Dr. med. vet.
DipECVDI

HOSPITAL NAME

Scottsdale VC

REFERRING VET

Dr. Magnussen



INVOICE

21921

The information and recommendations provided are based on the images presented by the referring veterinarian/sonographer. No evaluation can be communicated regarding pathology that was not visible in the image/video clips provided.

DATE

4/7/23

Thank you for this referral. If the clinical or image interpretation does not parallel your findings or if



PATIENT I can be of any further assistance please contact me.

Bug Camomile

Sebastian Schaub, Sebastian Schaub, DVM, Dr. med. vet. DipECVDI
sebast.schaub@gmail.com

SPECIES

Feline

BREED

DLH

SEX

Neutered Male

AGE

12

INTERPRETED BY

Sebastian Schaub,
DVM Dr. med. vet.
DipECVDI

HOSPITAL NAME

Scottsdale VC

REFERRING VET

Dr. Magnussen

INVOICE

21921

DATE

4/7/23