



**PATIENT PRESENTING CLINICAL SIGNS**

Rosie Cross Rosie presented as a referral for bleeding from the right side of nose for 2 weeks. Swelling present on right side of nose and under right eye.  
 Abnormal PE/Chem/CBC/UA Results: WBC 16.92 K/uL Neutrophils 13.96 K/uL MPV 13.3 fL  
 Phosphorus 1.8 mg/dL ALT 250 U/L

**SPECIES**

Canine

**COMPUTED TOMOGRAPHY OF THE SKULL**

A high resolution pre- and post-contrast CT study of the skull is provided for review.

**BREED**

Mixed

**COMPUTED TOMOGRAPHIC FINDINGS**

The tooth elements 301, 302 and 408 are absent. Advanced abrasion of the crowns of triadan 304&404 is noted.

**SEX**

Spayed Female

The right nasal cavity is occupied by soft tissue attenuating and heterogeneous contrast enhancing material. Advanced destruction of the associated conchal & turbinate structures is seen. The right maxillary and right nasal bone present moth eaten osteolytic lesions and the right nasal soft tissue material is protruding into the subcutaneous tissue at the dorsolateral aspect of the nose.

**AGE**

9 Years

Both temporomandibular joints present congruent joint spaces with even subchondral bone surfaces and are considered within normal limits.

**INTERPRETED BY**

Sebastian Schaub, DVM  
 Dr. med. vet. DipECVDI

Both tympanic bullae are aerated, the mucosal lining is not seen, the bony wall is smooth and thin. The external ear canals present moderate shell-like mineralization of the external ear canals.

**HOSPITAL NAME**

Neel Veterinary Hospital

The brain presents no deviation from normal anatomy and symmetry. The brain parenchyma is homogeneous and within normal limits for attenuation and distribution of contrast enhancement. The ventricular system is non-dilated and symmetric.

The submandibular and medial retropharyngeal lymph nodes are small and elongated with a normal short-to-long-axis-ratio is < 0.5, the attenuation and contrast enhancement pattern is uniform.

**REFERRING VET**

Dr. Deepan Kishore

**COMPUTED TOMOGRAPHIC DIAGNOSIS**

- Right sided biologically aggressive soft tissue neoplasia right nasal cavity with polyostotic aggressive osteolytic lesions of the right maxillary & nasal bone
- Absent triadan 301, 302 and 408
- Advanced abrasion of triadan 304&404
- Dystrophic mineralization external ear canals

**INVOICE**

51404

**INTERPRETATION OF THE FINDINGS & FURTHER RECOMMENDATIONS**

**DATE**

4-7-22

The CT study is consistent with a biologically aggressive soft tissue neoplasia originating from the right nasal cavity with extension of the mass into the subcutaneous tissue. Differentials include adenocarcinoma, squamous cell carcinoma, transitional cell carcinoma, lymphosarcoma, other. FNA sampling of the subcutaneous swelling or rhinoscopy including biopsy can be used as advanced diagnostic tests. Based on the results of the advanced diagnostic tests, the chances of



**PATIENT**

Rosie Cross

radiation therapy can be discussed with oncologist. The Adam tumor stage is T3.

Consider full tumor staging.

**SPECIES**

Canine

**BREED**

Mixed

**SEX**

Spayed Female

**AGE**

9 Years

**INTERPRETED BY**

Sebastian Schaub, DVM  
Dr. med. vet. DipECVDI

**HOSPITAL NAME**

Neel Veterinary  
Hospital

**REFERRING VET**

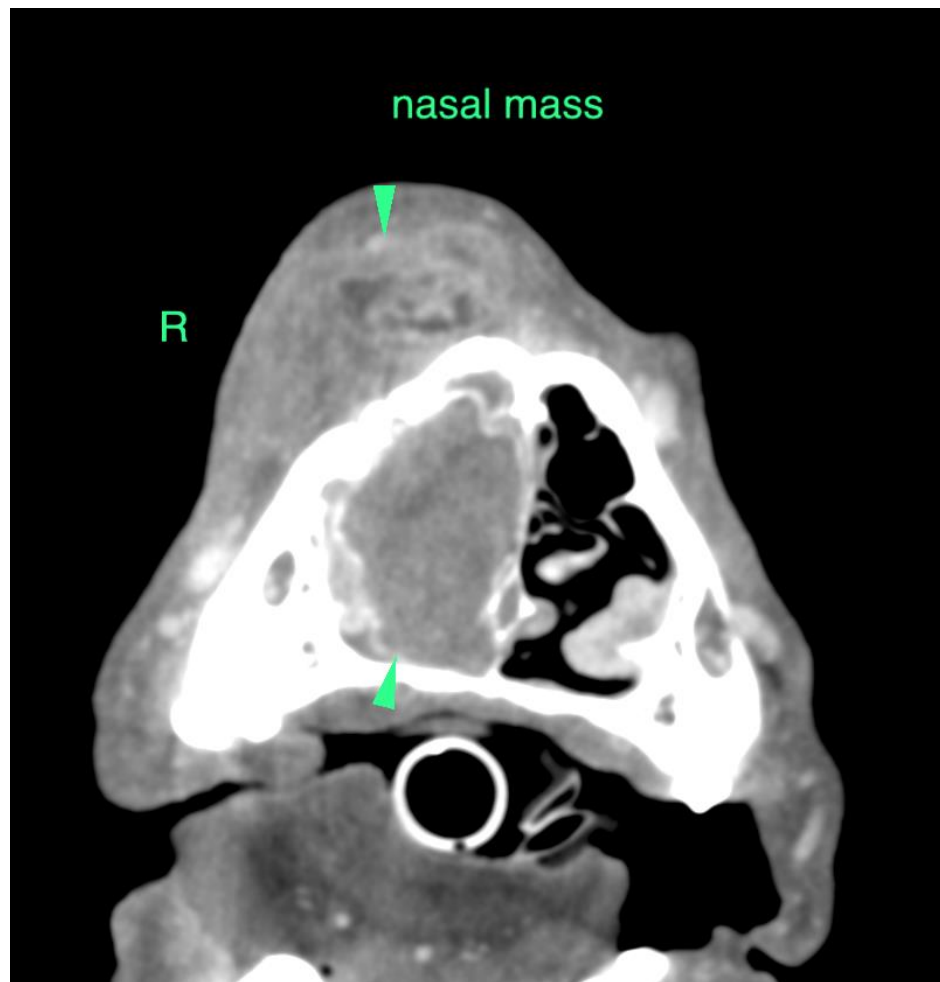
Dr. Deepan Kishore

**INVOICE**

51404

**DATE**

4-7-22





**PATIENT**

Rosie Cross

**SPECIES**

Canine

**BREED**

Mixed

**SEX**

Spayed Female

**AGE**

9 Years

**INTERPRETED BY**

Sebastian Schaub, DVM  
Dr. med. vet. DipECVDI

**HOSPITAL NAME**

Neel Veterinary  
Hospital

**REFERRING VET**

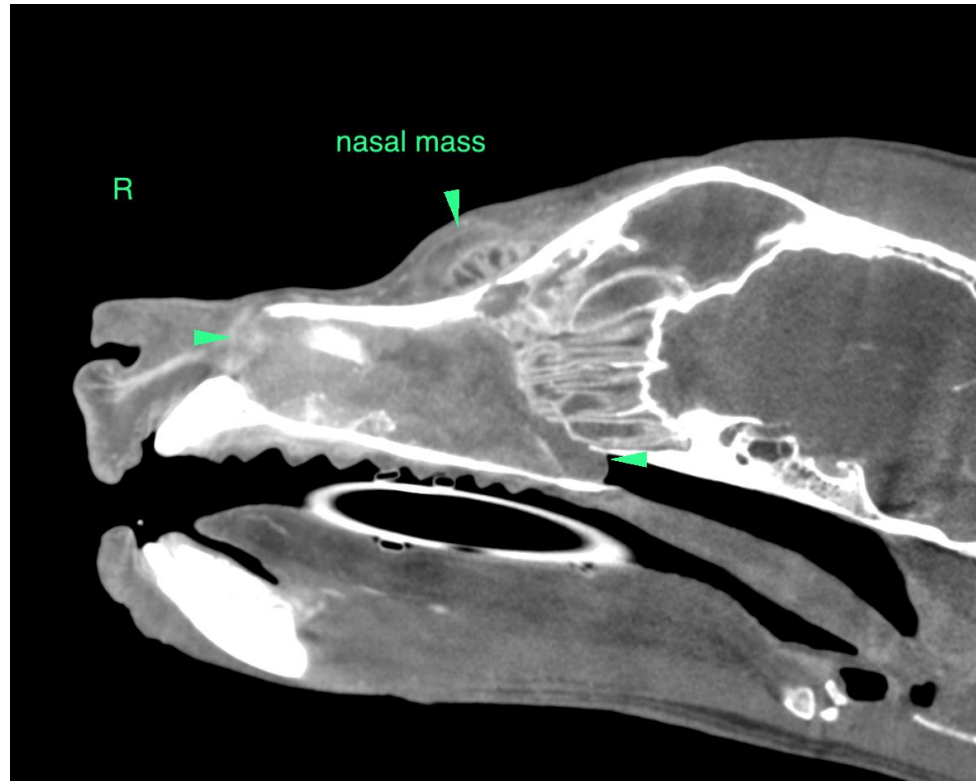
Dr. Deepan Kishore

**INVOICE**

51404

**DATE**

4-7-22



The information and recommendations provided are based on the images presented by the referring veterinarian/sonographer. No evaluation can be communicated regarding pathology that was not visible in the image/video clips provided.

Thank you for this referral. If the clinical or image interpretation does not parallel your findings or if I can be of any further assistance please contact me.

**Sebastian Schaub**, Sebastian Schaub, DVM, Dr. med. vet. DipECVDI  
sebast.schaub@gmail.com