



PATIENT

Henry Christie

PRESENTING CLINICAL SIGNS

Coughing. Has allergies is on Apoquel. 1kg weight loss in 1 month.

SPECIES

Canine

RADIOGRAPHIC STUDY OF THE THORAX

Radiographs of the thorax in three imaging planes are provided for review.

BREED

Cocker Spaniel

RADIOGRAPHIC FINDINGS

Multifocal mild spondylosis formation is seen along the thoracic spine

The extrathoracic soft tissues present homogeneous without abnormalities.

SEX

MN

The heart is of normal size and shape, there is no evidence of cardiac chamber or vascular enlargement. The pulmonary vasculature is within normal limits.

The cranial mediastinum presents the expected soft tissue opacity. The mediastinal width is less than twice the width of the vertebral column at the same level.

AGE

13 Years

The trachea is normal in diameter and presents the anticipated course. The luminal outline of the trachea is smooth.

Generalized mild to moderate thickening of the bronchial walls is seen.

INTERPRETED BY

Sebastian Schaub, DVM
Dr. med. vet. DipECVCI

The lung parenchyma presents the expected architecture and opacity; the intrapulmonary vascular branching is seen up to the third order lung vessels.

The diaphragm is well delineated with even surface and the expected mild cranial bulging of the diaphragmatic cupola.

HOSPITAL NAME

Sunridge Vet Clinic

RADIOGRAPHIC DIAGNOSIS

- Bronchial lung pattern
- Spondylosis deformans

REFERRING VET

Dr. Magill

INTERPRETATION OF THE FINDINGS & FURTHER RECOMMENDATIONS

The radiographic findings are suggestive for bronchitis. Primary inflammatory bronchitis (e.g. allergic. Lymphocytic plasmocytic, eosinophilic, mixed) and infectious bronchitis – viral, bacterial, parasitic – need to be considered.

INVOICE

51402

Bronchoscopy including a broncho-alveolar lavage would be ideal for further evaluation as well as a fecal exam to rule out lung worm infection. Consider complete blood work to screen for inflammatory changes.

DATE

4-7-22



PATIENT

Henry Christie

SPECIES

Canine

BREED

Cocker Spaniel

SEX

MN

AGE

13 Years

INTERPRETED BY

Sebastian Schaub, DVM
Dr. med. vet. DipECVDI

HOSPITAL NAME

Sunridge Vet Clinic

REFERRING VET

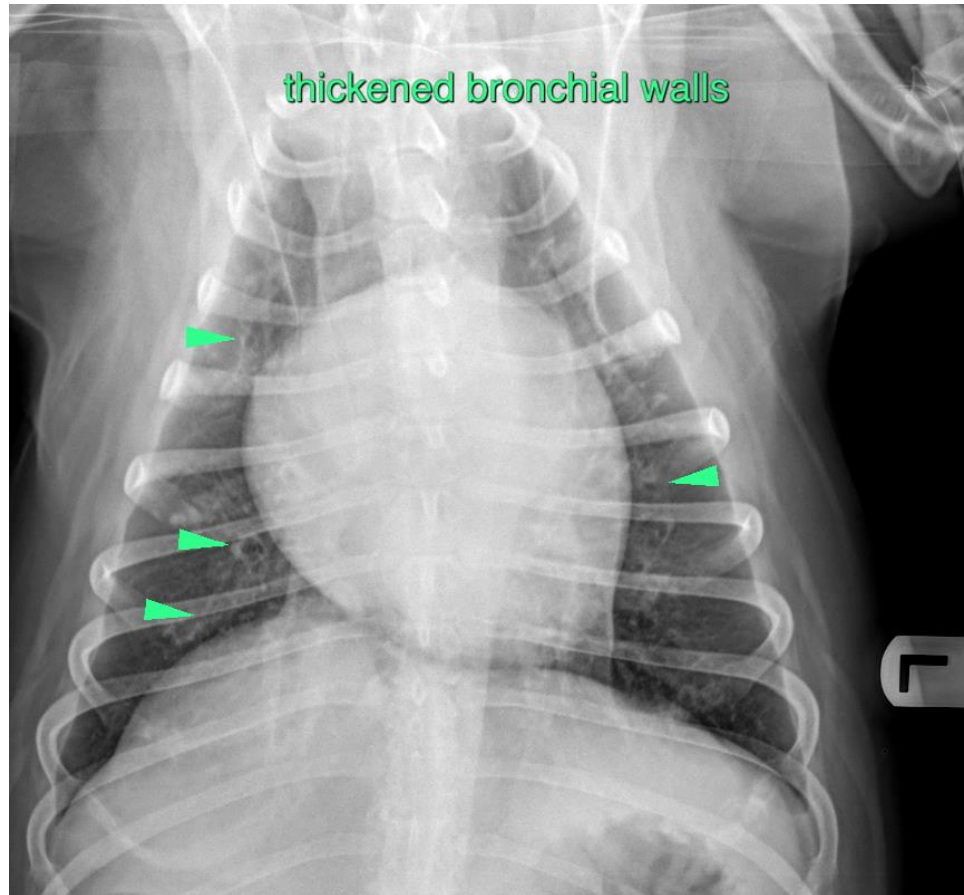
Dr. Magill

INVOICE

51402

DATE

4-7-22



The information and recommendations provided are based on the images presented by the referring veterinarian/sonographer. No evaluation can be communicated regarding pathology that was not visible in the image/video clips provided.

Thank you for this referral. If the clinical or image interpretation does not parallel your findings or if I can be of any further assistance please contact me.

Sebastian Schaub, Sebastian Schaub, DVM, Dr. med. vet. DipECVDI
sebast.schaub@gmail.com