



PATIENT PRESENTING CLINICAL SIGNS

Pepe Tevis Patient is a 9 week old intact male Boston Terrier named Pepe. Pepe presents for being hit by a golf cart this morning around 9am. The owner had the pet on the cart when he jumped off and was hit by the back tire. Patient immediately yelped and urinated on himself, his face appeared pale and he became unresponsive. Owner performed CPR and gave breaths. Patient on the way to a PDVM became more responsive. There at the PDVM they took radiographs suspecting a diaphragmatic hernia. Patient was then sent here for further care and work up. Patient prior to this event was doing well. Eating, drinking, urinating and defecating normally.

SPECIES

Canine

BREED

Boston Terrier

COMPUTED TOMOGRAPHY OF THE SKULL, THORAX AND ABDOMEN

A high resolution plain CT study of the skull, thorax and abdomen and a post-contrast CT study of the thorax are provided for review.

COMPUTED TOMOGRAPHIC FINDINGS

SEX

The growth plates of the skeletal structures are age related visible.

M

Skull

A well-defined, fracture line is running through the distal third of the right ramus of the mandible in a rostral to caudal direction. The fissure line is running through the tooth bud of triadan 410.

AGE

9 Weeks

The nasal cavity presents the expected aerated spaces between thin & even conchae and turbinates with smooth mucosal lining.

INTERPRETED BY

Both temporomandibular joints present congruent joint spaces with even subchondral bone surfaces and are considered within normal limits.

Sebastian Schaub, DVM
Dr. med. vet. DipECVDI

The osseous structures of the calvarium are intact.

Both tympanic bullae contain soft tissue material. The external ear canals are within normal limits.

HOSPITAL NAME

Critical Vet
Care/Suncoast
Veterinary

Thorax

The first to third right rib present with multiple transverse fractures and lateral deviation of the lateral ribs is present. The 4th to 10th right rib present a transverse fracture just distal to the costal head.

In the pleural cavity, a moderate amount of gravity, dependent, non-contrast enhancing soft tissue attenuating material is present. Pleural fissure lines are appreciated. The lung lobes are retracted from the thoracic wall and present a generalized decreased volume. Multiple regions with dystelectasis of the lung parenchyma are visible.

REFERRING VET

Dr. Young

The cardiovascular structures including the pulmonary vasculature are within normal limits.

INVOICE

Small incidental gas pockets are seen within the esophageal lumen, there is no evidence of abnormal dilation.

57689

Abdomen

The serosal fat presents normal attenuation behavior. There is no evidence of peritoneal effusion or peritonitis.

DATE

4-6-23

Both kidneys present within normal limits for size, shape and organ architecture.



PATIENT

Pepe Tevis The adrenal glands are within normal limits for size, shape and organ architecture.
Both liver and spleen present with normal shape, even surface, uniformly attenuating parenchyma.

SPECIES

The position, delineation and content of the gastrointestinal tract are considered within normal limits throughout.

Canine

The bony and surrounding soft tissue structures reveal no abnormalities.

BREED

Boston Terrier

COMPUTED TOMOGRAPHIC DIAGNOSIS

- Moderate pleural effusion
- Acute closed, non-displaced transverse fracture ramus right mandible
- Right serial costal fracture
- Bilateral effusion tympanic bullae

SEX

M

INTERPRETATION OF THE FINDINGS & FURTHER RECOMMENDATIONS

The pleural effusion is considered as a sequela to the trauma and hemothorax is considered likely – likely secondary to the costal fractures.

AGE

9 Weeks

Conservative management of the mandibular fracture is considered as the therapy of choice – recommend discussing options with dentist. As the fracture line is involving the tooth bud of triadan 410, there might be damage of the respective tooth bud.

INTERPRETED BY

The fluid in the tympanic bulla is likely a sequela to the traumatic insult.

Sebastian Schaub, DVM
Dr. med. vet. DipECVDI

HOSPITAL NAME

Critical Vet
Care/Suncoast
Veterinary

REFERRING VET

Dr. Young

INVOICE

57689

DATE

4-6-23



PATIENT

Pepe Tevis

SPECIES

Canine

BREED

Boston Terrier

SEX

M

AGE

9 Weeks

INTERPRETED BY

Sebastian Schaub, DVM
Dr. med. vet. DipECVDI

HOSPITAL NAME

Critical Vet
Care/Suncoast
Veterinary

REFERRING VET

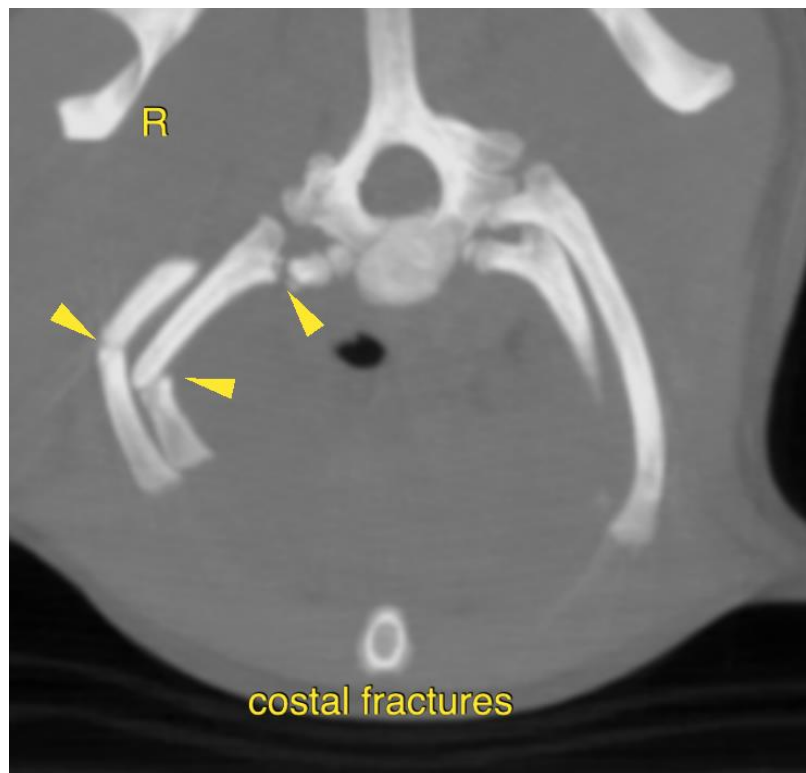
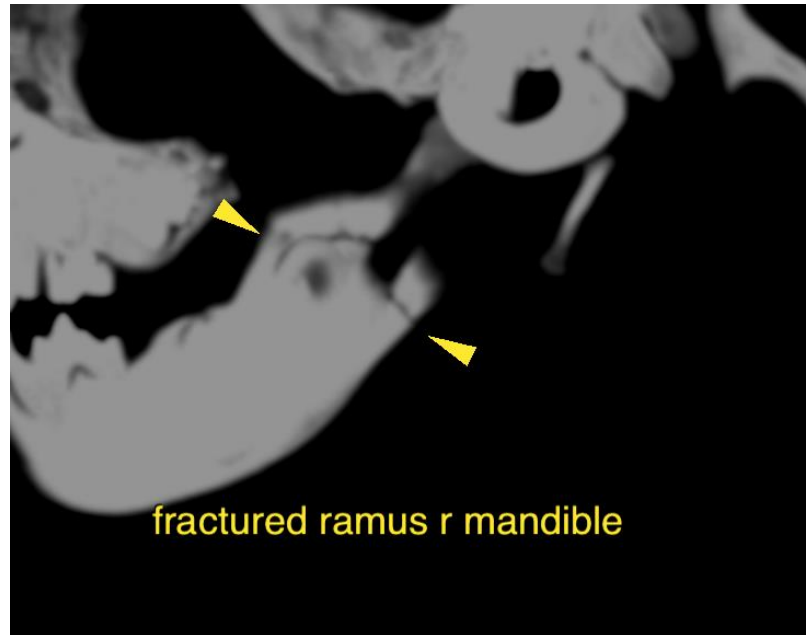
Dr. Young

INVOICE

57689

DATE

4-6-23





PATIENT

Pepe Tevis

SPECIES

Canine

BREED

Boston Terrier

SEX

M

AGE

9 Weeks

INTERPRETED BY

Sebastian Schaub, DVM
Dr. med. vet. DipECVDI

HOSPITAL NAME

Critical Vet
Care/Suncoast
Veterinary

REFERRING VET

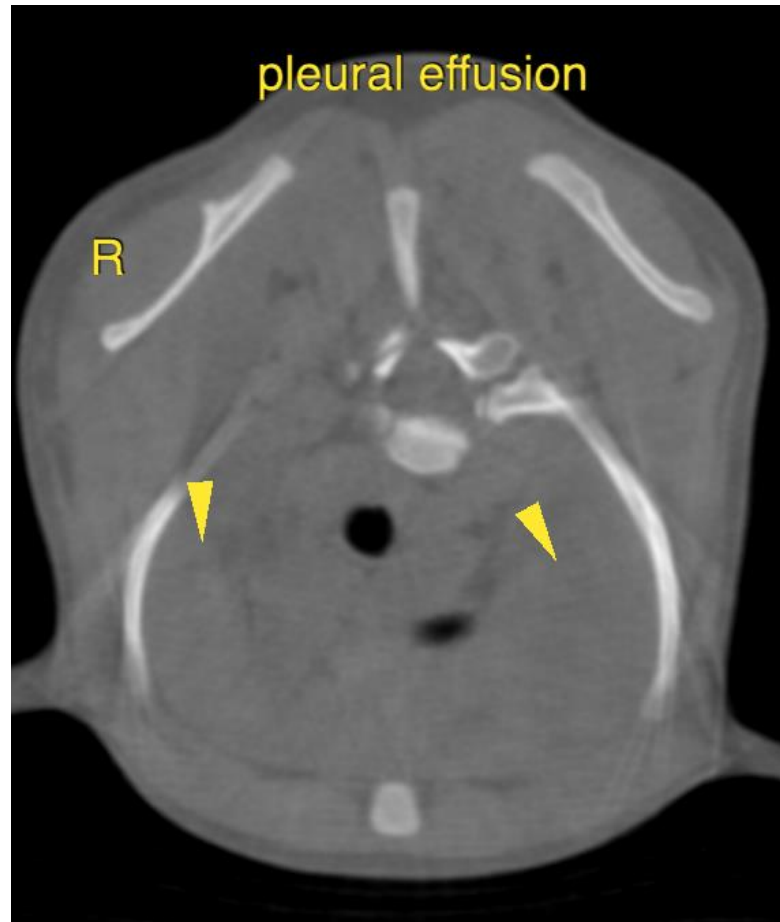
Dr. Young

INVOICE

57689

DATE

4-6-23



The information and recommendations provided are based on the images presented by the referring veterinarian/sonographer. No evaluation can be communicated regarding pathology that was not visible in the image/video clips provided.

Thank you for this referral. If the clinical or image interpretation does not parallel your findings or if I can be of any further assistance please contact me.

Sebastian Schaub, Sebastian Schaub, DVM, Dr. med. vet. DipECVDI
sebast.schaub@gmail.com