



**PATIENT PRESENTING CLINICAL SIGNS**

Ollie Pease nasopharyngeal stenosis, history of stenting on 8 /2021. sneezed out nasopharyngeal stent on 1/17/22. Fistula noted at that time.

**SPECIES COMPUTED TOMOGRAPHY OF THE SKULL**

Canine A high resolution plain CT study of the skull is provided for review.

**COMPUTED TOMOGRAPHIC FINDINGS**

**BREED** The tooth elements 106, 206, 311 and 411 are absent. A persistent deciduous tooth 606 is noted.

Pomeranian The osseous ring of the choana is narrowed with complete obliteration of the choana. In both nasal cavities, gravity dependent soft tissue material is seen. Destruction of the nasal conchal structures is appreciated. The rostral segment of the soft palate presents a defect in the sagittal plane – measuring 5 mm in length.

**SEX**

Male Neutered Both temporomandibular joints present congruent joint spaces with even subchondral bone surfaces and are considered within normal limits.

**AGE**

2 Years, 7 Months

Both tympanic bullae are aerated, the mucosal lining is not seen, the bony wall is smooth and thin. The external ear canals are within normal limits.

**COMPUTED TOMOGRAPHIC DIAGNOSIS**

**INTERPRETED BY**

Sebastian Schaub, DVM  
Dr. med. vet. DipECVDI

- History of congenital nasopharyngeal stenosis/stenosis due to osseous malformation & soft tissue membrane
- Small defect base of soft palate with oropharyngeal fistula formation
- Secondary destructive rhinitis
- Absent triadan 106, 206, 311, 411
- Persistent 606

**HOSPITAL NAME**

Animal Surgical  
Center

**INTERPRETATION OF THE FINDINGS & FURTHER RECOMMENDATIONS**

The CT study is fitting the history, the defect in the soft palate has not been present in the preceding CT study.

**REFERRING VET**

All Creatures  
Veterinary Service

**INVOICE**

57692

**DATE**

4-6-23



**PATIENT**

Ollie Pease

**SPECIES**

Canine

**BREED**

Pomeranian

**SEX**

Male Neutered

**AGE**

2 Years, 7 Months

**INTERPRETED BY**

Sebastian Schaub, DVM  
Dr. med. vet. DipECVDI

**HOSPITAL NAME**

Animal Surgical  
Center

**REFERRING VET**

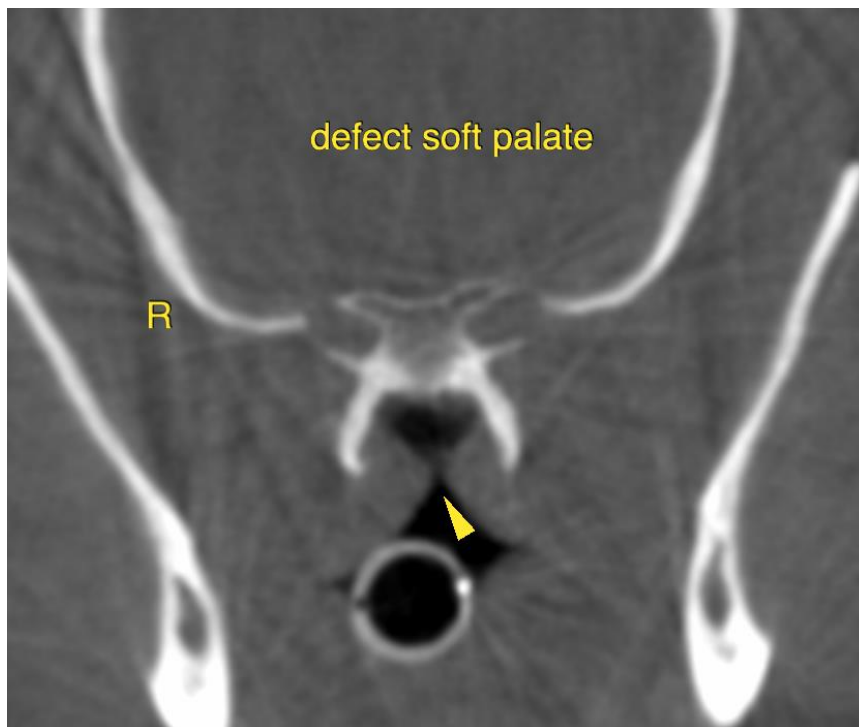
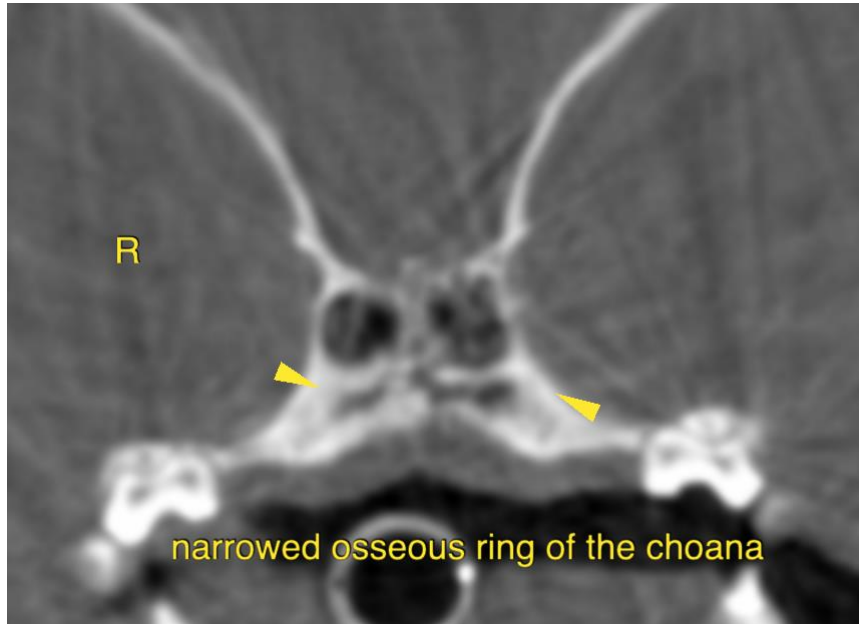
All Creatures  
Veterinary Service

**INVOICE**

57692

**DATE**

4-6-23





**PATIENT**

Ollie Pease

The information and recommendations provided are based on the images presented by the referring veterinarian/sonographer. No evaluation can be communicated regarding pathology that was not visible in the image/video clips provided.

**SPECIES**

Canine

Thank you for this referral. If the clinical or image interpretation does not parallel your findings or if I can be of any further assistance please contact me.

**BREED**

Pomeranian

**Sebastian Schaub**, Sebastian Schaub, DVM, Dr. med. vet. DipECVDI  
sebast.schaub@gmail.com

**SEX**

Male Neutered

**AGE**

2 Years, 7 Months

**INTERPRETED BY**

Sebastian Schaub, DVM  
Dr. med. vet. DipECVDI

**HOSPITAL NAME**

Animal Surgical  
Center

**REFERRING VET**

All Creatures  
Veterinary Service

**INVOICE**

57692

**DATE**

4-6-23