



**PATIENT PRESENTING CLINICAL SIGNS**

Marty McBride Annual exam reveal multiple sq masses, many quite large and unchanged. mm wasting over pelvic limbs  
 o  
 Abnormal PE/Chem/CBC/UA Results: pending cbc chem ua TT4 4dx and fecal

**SPECIES RADIOGRAPHIC STUDY OF THE THORAX & ABDOMEN**

Canine A complete set of radiographs of the thorax & abdomen is provided for review.

**RADIOGRAPHIC FINDINGS**

**BREED** Thorax

Mix The surrounding bony structures are within normal limits.

**SEX** In the subcutaneous tissue along the right thoracic wall, a well-defined, uniform fat opaque ovoid shaped mass is seen, measuring 15.7 x 5.6 cm in size. Multiple fat opaque subcutaneous lesions are seen along the ventral and left lateral thoracic wall.

MN The heart is of normal size and shape, there is no evidence of cardiac chamber or vascular enlargement. The pulmonary vasculature is within normal limits.

**AGE** The cranial mediastinum presents the expected soft tissue opacity. The mediastinal width is less than twice the width of the vertebral column at the same level.

15 Years The trachea is normal in diameter and presents the anticipated course. The luminal outline of the trachea is smooth.

**INTERPRETED BY**

Sebastian Schaub, DVM  
 Dr. med. vet. DipECVDI

The bronchial tree presents with thin walls and tapers uniformly towards the periphery as expected.

The lung field is extending up to the level of the level of the caudal vertebral endplate T10 – expiration. The lung parenchyma presents the expected architecture and has a generalized increased radiopacity; the intrapulmonary vascular branching is seen up to the third order lung vessels.

**HOSPITAL NAME**

Northshore  
 Veterinary Hospital

The diaphragm is well delineated with even surface and the expected mild cranial bulging of the diaphragmatic cupola.

Abdomen

**REFERRING VET**

Brita Kiffney

Moderate spondylosis formation is seen along the cranial lumbar spine.

In the subcutaneous tissue at the right caudoventral abdominal wall, a fat opaque mass with a heterogeneous soft tissue opaque, ovoid shaped region is seen. Multiple subcutaneous fat opaque swellings are noted along the lateral abdominal wall.

**INVOICE**

57685

No abnormalities of the extraabdominal soft tissues are noted. The abdominal wall is smooth and thin.

The serosal detail is maintained throughout the peritoneal and retroperitoneal space.

The hepatic volume is mildly increased and the caudoventral hepatic margins are rounded.

**DATE**

4-6-23

The splenic head is in the anticipated position and within normal limits for size and opacity. The splenic body and tail are considered normal for position, size, shape and opacity.

Both kidneys are seen and present with normal size, shape, delineation and opacity. The urinary bladder is in its anticipated position. No radiopaque calculi are noted throughout the upper and lower



**PATIENT** urinary tract.

Marty McBride The stomach is in its anticipated position and presents normal content.

The small intestinal loops are of even diameter and non-dilated, a small amount of gas is seen within the small intestinal loops and considered within normal limits.

**SPECIES**

The colon is seen in the expected position and presents with appropriate content.

Canine

**RADIOGRAPHIC DIAGNOSIS**

**BREED**

- Large subcutaneous lipoma right thoracic wall
- Suspect lipoma right caudoventral abdominal wall with intralisions soft tissue opaque lesion
- Multiple small subcutaneous lipomas ventral thoracic wall
- Mild hepatomegaly
- Spondylosis deformans
- No evidence of pulmonary metastatic disease

Mix

**SEX**

MN

**INTERPRETATION OF THE FINDINGS & FURTHER RECOMMENDATIONS**

The clinically appreciated subcutaneous masses are suggestive for lipomas. The intralisions soft tissue opacity within the mass along the caudoventral abdominal wall can present a zone with fat necrosis, however a soft tissue neoplasm might be a potential.

**AGE**

15 Years

Potentials for the hepatomegaly include metabolic hepatic disease/steroid induced hepatopathy, hepatitis or neoplastic infiltration. Ultrasound including FNA sampling can be used as minimally advanced diagnostic tests.

**INTERPRETED BY**

Sebastian Schaub, DVM  
Dr. med. vet. DipECVDI

**HOSPITAL NAME**

Northshore  
Veterinary Hospital

**REFERRING VET**

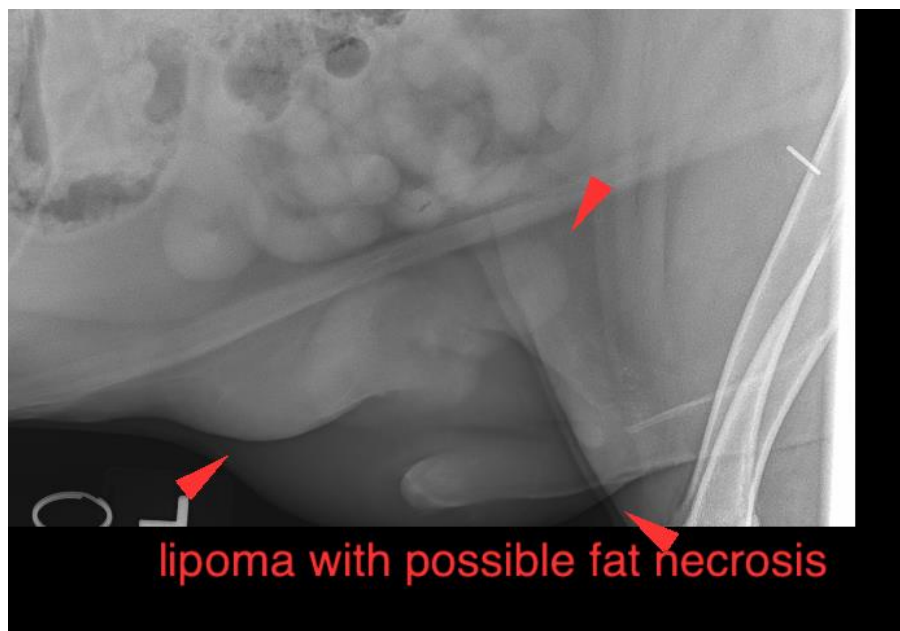Brita Kiffney

**INVOICE**

57685

**DATE**

4-6-23





**PATIENT**

Marty McBride

**SPECIES**

Canine

**BREED**

Mix

**SEX**

MN

**AGE**

15 Years

**INTERPRETED BY**

Sebastian Schaub, DVM  
Dr. med. vet. DipECVDI

**HOSPITAL NAME**

Northshore  
Veterinary Hospital

**REFERRING VET**

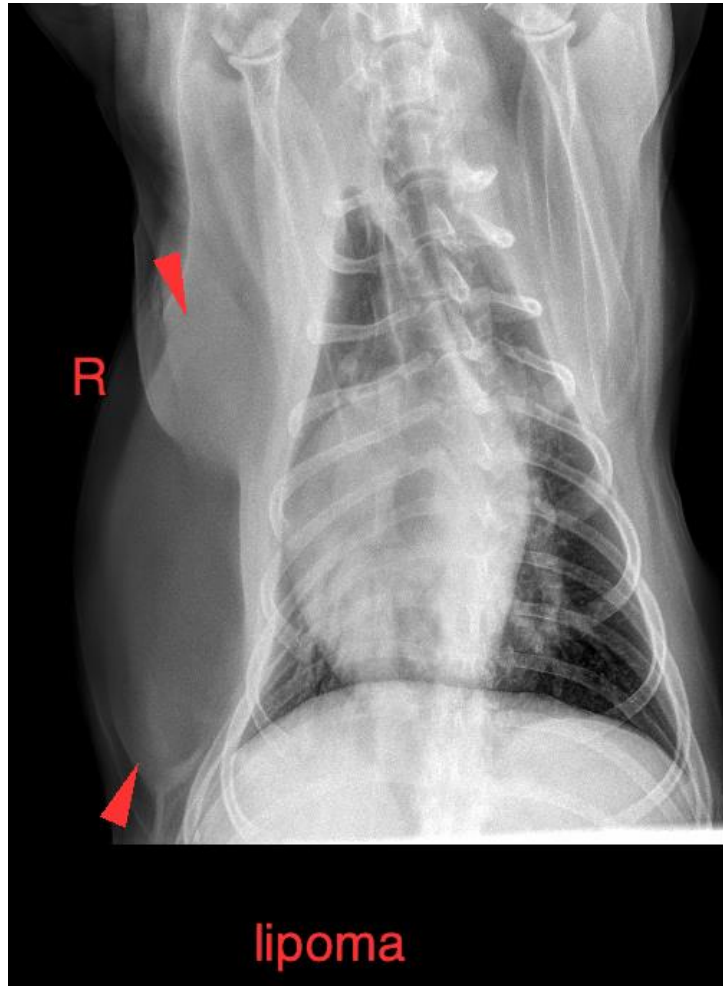
Brita Kiffney

**INVOICE**

57685

**DATE**

4-6-23



The information and recommendations provided are based on the images presented by the referring veterinarian/sonographer. No evaluation can be communicated regarding pathology that was not visible in the image/video clips provided.

Thank you for this referral. If the clinical or image interpretation does not parallel your findings or if I can be of any further assistance please contact me.

**Sebastian Schaub**, Sebastian Schaub, DVM, Dr. med. vet. DipECVDI  
sebast.schaub@gmail.com