



PATIENT PRESENTING CLINICAL SIGNS

Lamby Garbutt Heavy and abdominal breathing. Need to rule out mediastinal mass vs lymphoma vs others
 Abnormal PE/Chem/CBC/UA Results: Bloodwork owner presented us with is attached.

SPECIES RADIOGRAPHIC STUDY OF THE THORAX

Feline Radiographs of the thorax in three imaging planes are provided for review.

RADIOGRAPHIC FINDINGS

BREED The surrounding bony structures are within normal limits.

Domestic Shorthair The extrathoracic soft tissues present homogeneous without abnormalities.

SEX In the pleural space of the right hemithorax, a moderate amount of soft tissue material is seen. The right lung lobes are retracted from the thoracic wall and present a decreased volume. Pleural fissure lines are appreciated in the left hemithorax.

Spayed Female The heart is of normal size and shape, there is no evidence of cardiac chamber or vascular enlargement. The pulmonary vasculature is within normal limits.

AGE The trachea is normal in diameter and presents the anticipated course. The luminal outline of the trachea is smooth.

17 Years The lung parenchyma presents a generalized mild ground glass opacification – secondary to the pleural effusion.

INTERPRETED BY

The diaphragm is well delineated with even surface and the expected mild cranial bulging of the diaphragmatic cupola.

Sebastian Schaub, DVM
 Dr. med. vet. DipECVDI

RADIOGRAPHIC DIAGNOSIS

- Pleural effusion, R>>L

HOSPITAL NAME

Truscott Animal Hospital

INTERPRETATION OF THE FINDINGS & FURTHER RECOMMENDATIONS

There is evidence of pleural effusion, an underlying cause cannot be specified in the radiographic study there is no sign of mass effect. Differentials can include pyothorax, pancreatitis, cardiac disease, hepatic disease, inflammatory, paraneoplastic, other. Further workup warrants fluid analysis. An ultrasound evaluation of the cranial mediastinum is possible using the pleural effusion as acoustic window to screen for mass effaced by the pleural effusion and will allow ruling out underlying cardiac disease.

REFERRING VET

Dr. Medhat Meawad

INVOICE

57693

DATE

4-6-23



PATIENT

Lamby Garbutt

SPECIES

Feline

BREED

Domestic Shorthair

SEX

Spayed Female

AGE

17 Years

INTERPRETED BY

Sebastian Schaub, DVM
Dr. med. vet. DipECVDI

HOSPITAL NAME

Truscott Animal
Hospital

REFERRING VET

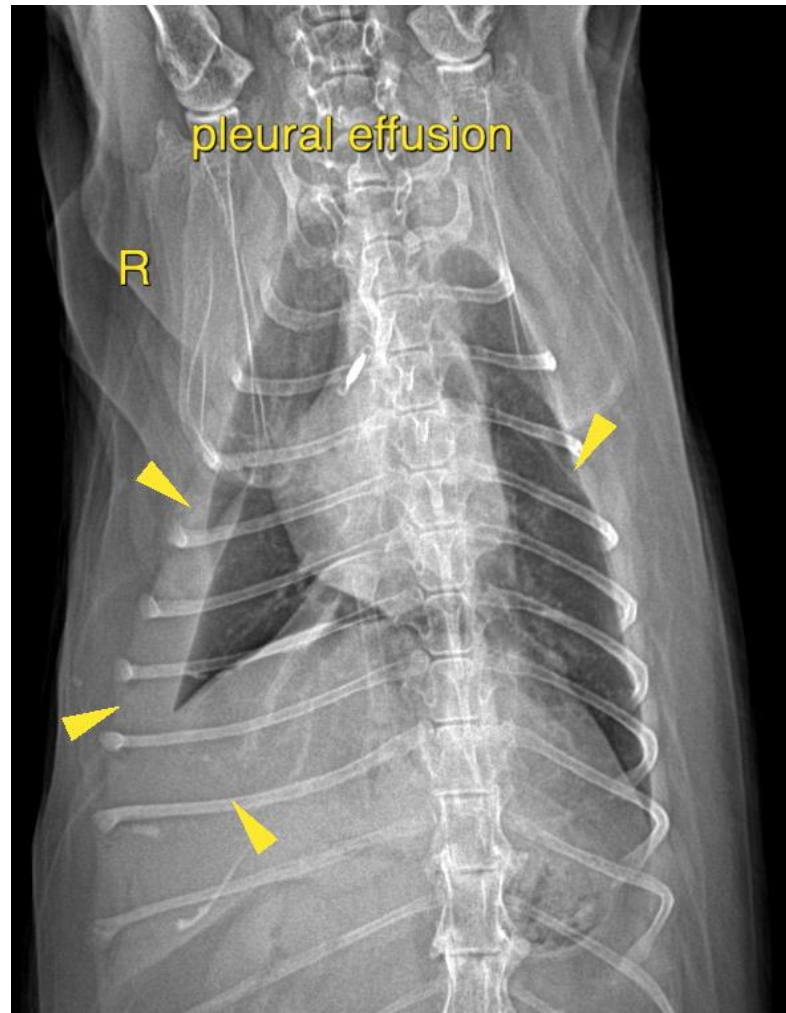
Dr. Medhat Meawad

INVOICE

57693

DATE

4-6-23



The information and recommendations provided are based on the images presented by the referring veterinarian/sonographer. No evaluation can be communicated regarding pathology that was not visible in the image/video clips provided.

Thank you for this referral. If the clinical or image interpretation does not parallel your findings or if I can be of any further assistance please contact me.

Sebastian Schaub, Sebastian Schaub, DVM, Dr. med. vet. DipECVDI
sebast.schaub@gmail.com